

### In this article...

- How blood and immune cells are produced and developed by the lymphatic system
- Clinical significance of the primary and secondary lymphoid organs
- How the lymphatic system mounts an immune response and filters pathogens

# The lymphatic system 2: structure and function of the lymphoid organs



Nursing Times  
Self-assessment

## Key points

**The lymphoid organs include the red bone marrow, thymus, spleen and clusters of lymph nodes**

**Blood and immune cells are produced inside the red bone marrow, during a process called haematopoiesis**

**The thymus secretes hormones that are essential for normal immune function and develops T-lymphocytes**

**The spleen mounts the immune response and removes micro-organisms and damaged red blood cells from circulation**

**Lymph nodes are clustered throughout the body and filter pathogens from lymph, swelling when mounting an immune response**

**Authors** Yamni Nigam is professor in biomedical science; John Knight is associate professor in biomedical science; both at the College of Human and Health Sciences, Swansea University.

**Abstract** This article is the second in a six-part series about the lymphatic system. It discusses the role of the lymphoid organs, which is to develop and provide immunity for the body. The primary lymphoid organs are the red bone marrow, in which blood and immune cells are produced, and the thymus, where T-lymphocytes mature. The lymph nodes and spleen are the major secondary lymphoid organs; they filter out pathogens and maintain the population of mature lymphocytes.

**Citation** Nigam Y, Knight J (2020) The lymphatic system 2: structure and function of the lymphoid organs. *Nursing Times* [online]; 116: 11, 44-48.

This article discusses the major lymphoid organs and their role in developing and providing immunity for the body. The lymphoid organs include the red bone marrow, thymus, spleen and clusters of lymph nodes (Fig 1). They have many functional roles in the body, most notably:

- Production of blood cells, including red blood cells (erythrocytes), white blood cells (leucocytes) and platelets (thrombocytes);
- Removal of damaged red blood cells;
- Maturation of immune cells;
- Trapping foreign material.

The red bone marrow and thymus are considered to be primary lymphoid organs, because the majority of immune cells originate in them.

### The red bone marrow

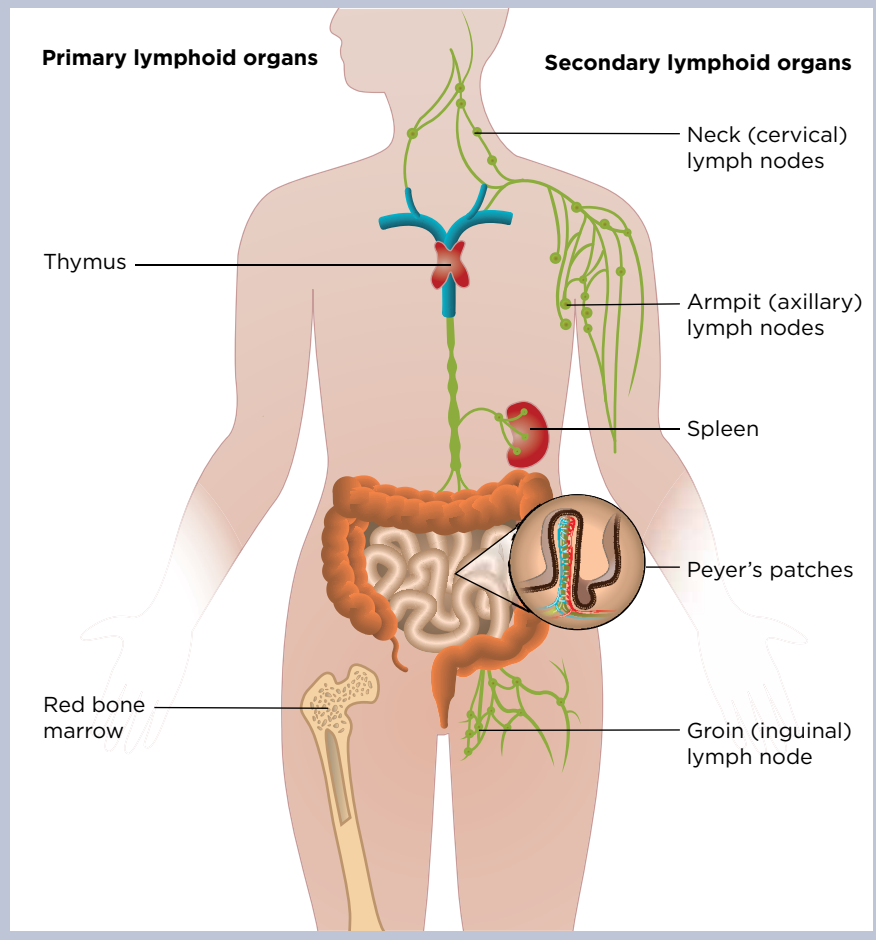
Bone marrow is a soft, gelatinous tissue present in the central cavity of long bones such as the femur and humerus. Blood cells and immune cells arise from the bone marrow; they develop from immature stem cells (haemocytoblasts), which follow distinct developmental pathways to

become either erythrocytes, leucocytes or platelets. Stem cells rapidly multiply to make billions of blood cells each day; this process is known as haematopoiesis and is outlined in Fig 2.

To ensure there is a continuous production and differentiation of blood cells to replace those lost to function or age, haematopoietic stem cells are present through adulthood. In the embryo, blood cells are initially made in the yolk sac but, as development of the embryo proceeds, this function is taken over by the spleen, lymph nodes and liver. Later in gestation, the bone marrow takes over most haematopoietic functions so that, at birth, the whole skeleton is filled with red bone marrow.

Red bone marrow produces all erythrocytes, leucocytes and platelets. Haematopoietic stem cells in the bone marrow follow either the myeloid or lymphoid lineages to create distinct blood cells (Fig 2); these include myeloid progenitor cells (monocytes, macrophages, neutrophils, basophils, eosinophils, erythrocytes, dendritic cells and platelets), and lymphoid progenitor cells (T-lymphocytes, B-lymphocytes and natural killer cells).

Fig 1. The lymphoid organs in adults



weighs around 40g, but in a middle-aged adult it may have shrunk sufficiently to be difficult to locate. By 20 years of age, the thymus is 50% smaller than it was at birth, and by 60 years of age it has shrunk to a sixth of its original size (Bilder, 2016); this is called thymic involution

Each of the two lobes of the thymus is surrounded by a capsule, within which are numerous small lobules – typically measuring 2-3mm in width – which are held together by loose connective tissue. Each lobule consists of follicles that are composed of a framework of thymosin-secreting epithelial cells and a population of T-lymphocytes; these cells are commonly referred to as T-cells (the ‘T’ denotes their origin as mature cells from the thymus). Lobules have two distinct areas:

- A dense outer cortex that is rich in actively dividing T-cells;
- An inner medulla, which is much paler in colour and functions as an area of T-cell maturation.

In addition to being a major lymphoid organ, the thymus is also recognised as part of the endocrine system because it secretes a family of hormones collectively referred to as thymosin; this is a group of several structurally related hormones secreted by the thymic epithelial cells. These hormones are essential for normal immune function and many members of the thymosin family are used therapeutically to treat cancers, infections and diseases such as multiple sclerosis (Severa et al, 2019).

### Role in T-cell maturation

T-cells originate as haematopoietic stem cells from the red bone marrow (Fig 2). A population of these haematopoietic stem cells infiltrate the thymus, dividing further within the cortical regions of the lobules then migrating into the medullary regions to mature into active T-cells; this process of T-cell maturation is controlled by the hormone thymosin. A proportion of these mature T-cells continually migrate from the thymus into the blood and other lymphoid organs (spleen and lymph nodes), where they play a major role in the body’s specific immune responses (which will be discussed in detail in part 3 of this series). The importance of these cells is apparent in patients who have depleted T-cell populations, such as those infected with HIV.

One of the most important functions of the thymus is programming T-cells to recognise ‘self’ antigens through a process called thymic education. This process

Some lymphoid cells (lymphocytes) begin life in the red bone marrow and become fully formed in the lymphatic organs, including the thymus, spleen and lymph nodes. As puberty is reached and growth slows down, physiological conversion occurs, changing red bone marrow to yellow bone marrow. This entire process is completed by the age of 25 years, when red bone marrow distribution shows its adult pattern in the bones.

The pattern is characterised by:

- The presence of red bone marrow in the axial skeleton (the vertebral bodies, sacral bone and medial parts of the hip bones) and articular ends of the humeral and femoral bones;
- The most distal parts of the skeleton being filled with yellow bone marrow only, which mainly acts as a store for fats, providing sustenance and maintaining the correct environment for the bone to function.

However, under particular conditions, such as severe blood loss or fever, the yellow marrow may revert back to red marrow (Malkiewicz and Dziezic 2012).

### Bone marrow diseases and transplants

Any disease or disorder that poses a threat to the bone marrow can affect many body systems, especially if it prevents stem cells from turning into essential cells. Those known to damage the marrow’s productive ability and destroy stem cells include:

- Leukaemia;
- Hodgkin’s lymphoma;
- Other lymphomas.

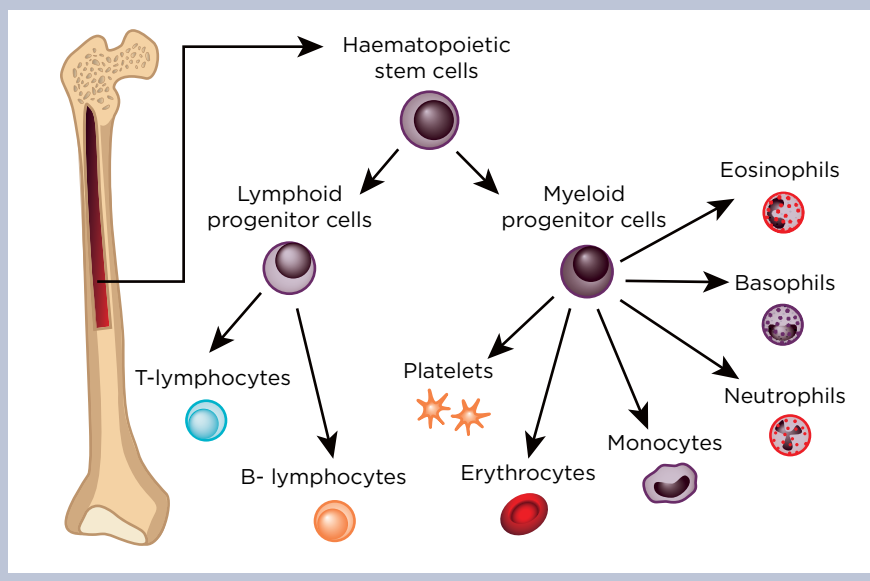
A growing number of diseases can be treated with a bone marrow transplant or haematopoietic stem cell transfer; this is often achieved by harvesting suitable donor stem cells from the posterior iliac crests of the hip bone, where the concentration of red bone marrow is highest.

### The thymus

The thymus gland is a bi-lobed, pinkish-grey organ located just above the heart in the mediastinum, where it rests below the sternum (breastbone). Structurally, the thymus resembles a small bow tie, which gradually atrophies (shrinks) with age. In pre-pubescent, the thymus is a relatively large and very active organ that, typically,

## Clinical Practice Systems of life

Fig 2. Haematopoiesis



allows mature T-cells to distinguish foreign, and therefore potentially pathogenic, material from antigens that belong to the body. It has been demonstrated that removal of the thymus may lead to an increase in autoimmune diseases, as this ability to recognise self is diminished (Sherer et al, 1999).

### Clinical significance

Diseases of the thymus include thymic cancer and myasthenia gravis (MG). MG occurs when the thymus produces antibodies that block or destroy the muscle-receptor sites, causing the muscles to become weak and easily tired. It most commonly affects muscles that control the eyes and eyelids, resulting in droopy eyelids and difficulty making facial expressions; chewing, swallowing and speaking also become difficult. MG can affect people of any age, but typically starts in women aged <40 years and men aged >60 years.

In most cases of either MG or thymic cancer, thymectomy is recommended. Patients who have had a thymectomy may develop an immunodeficiency known as Good syndrome, which increases their susceptibility to bacterial, fungal and viral opportunistic pathogens; this condition is, however, relatively rare.

### The spleen

The spleen and lymph nodes are two major secondary lymphoid organs that play key roles in:

- Filtering out and destroying unwanted pathogens;
- Maintaining the population of mature

lymphocytes (which are white blood cells) to enable the adaptive immune response to begin.

When foreign antigens reach these organs, they initiate lymphocyte activation and subsequent clonal expansion and maturation of these important white blood cells. Mature lymphocytes can then leave the secondary organs to enter the circulation, or travel to other areas, and target foreign antigens.

The spleen is the largest lymphoid organ. Situated in the upper left hypochondriac region of the abdominal cavity, between the diaphragm and the fundus of the stomach, it primarily functions as a filter for the blood, bringing it into close contact with scavenging phagocytes (white blood cells in the spleen that will seek out and 'eat' any pathogens in the blood) and lymphocytes.

Due to its extensive vascularisation, the spleen is a dark-purplish oval-shaped organ; in adults it is approximately 12cm long, 7cm wide and weighs around 150g. However, the size of the spleen can vary with circumstance: it diminishes in starvation, after heavy exercise and following severe haemorrhage (Gujar et al, 2017), and recent investigations indicate an increase in size in well-fed individuals and during the ingestion of food (Garnitschnig et al, 2020).

The spleen (Fig 3) is enclosed in a dense, fibro-elastic capsule that protrudes into the organ as trabeculae; these trabeculae constitute the organ's framework. Blood enters the spleen from the splenic artery and leaves via the splenic vein, both of which are at the hilum; the splenic vein

eventually becomes a tributary of the hepatic portal vein.

The spleen is made up of two regions:

- Stroma – comprising the dense outer capsule with its trabeculae, some fibres and fibroblasts (cells that secrete connective tissue collagen);
- Parenchyma – composed of two types of intermingling tissue called white pulp and red pulp.

White pulp is a mass of germinal centres of dividing B-lymphocytes (B-cells), surrounded by T-cells and accessory cells, including macrophages and dendritic cells; these cells are arranged as lymphatic nodules around branches of the splenic artery. As blood flows into the spleen via the splenic artery, it enters smaller, central arteries of the white pulp, eventually reaching the red pulp. The red pulp is a spongy tissue, accounting for 75% of the splenic volume (Pivkin et al, 2016); it consists of blood-filled venous sinuses and splenic cords.

Splenic cords are made up of red and white blood cells and plasma cells (antibody-producing B-cells); therefore, the red pulp primarily functions as a filtration system for the blood, whereas the white pulp is where adaptive T- and B-cell responses are mounted. The colour of the white pulp is derived from the closely packed lymphocytes and the red pulp's colour is due to high numbers of erythrocytes (Stewart and McKenzie, 2002).

### Functions

The spleen has three major functions:

- To mount an immune response and remove micro-organisms from circulation;
- To destroy damaged and worn-out red blood cells;
- To store platelets (and blood).

The spleen's main immunological function is to remove micro-organisms from circulation. The lymphatic nodules are arranged as sleeves around the blood vessels, bringing blood into the spleen. Within the white pulp are splenic nodules called Malpighian corpuscles, which are rich in B-cells, so this portion of lymphoid tissue is quick to respond to foreign antigenic stimulation by producing antibodies. The walls of the meshwork of sinuses in the red pulp also contain phagocytes that engulf foreign particles and cell debris, effectively filtering and removing them from circulation.

In the spleen's destruction of old and senescent red blood cells, they are digested by phagocytic macrophages in the red pulp. The haemoglobin is then split apart into haem and globin. The globin is broken

## Clinical Practice Systems of life

down into its constituent amino acids, which can be utilised in the synthesis of a new protein. Haem consists of an iron atom surrounded four non-iron (pyrrole) rings.

The iron is removed and transported to be stored as ferritin, then reused to make new haemoglobin in the red bone marrow; macrophages convert the pyrrole rings into the green pigment biliverdin and then into the yellow pigment bilirubin. Both are transported to the liver bound to plasma albumin. Bilirubin, the more toxic pigment, is conjugated in the liver to form a less toxic compound, which is excreted in bile.

The red pulp partly serves to store a large reserve of the body's platelets – up to a third of the total platelet supply. In some animals – particularly athletic mammals such as horses, greyhounds and foxes – the spleen is also an important reservoir of blood, which is released into circulation during times of stress to improve aerobic performance. In humans, however, the spleen contributes only a small percentage of blood cells into active circulation under physiological stress; the total stored blood volume is believed to be only 200-250ml (Bakovic et al, 2005). The capsule of the spleen may contract following haemorrhage, releasing this reserve into circulation in the body.

The spleen also plays a minor role in haematopoiesis: usually occurring in foetuses of up to five months' gestation, erythrocytes, along with the bone marrow, are produced by the spleen.

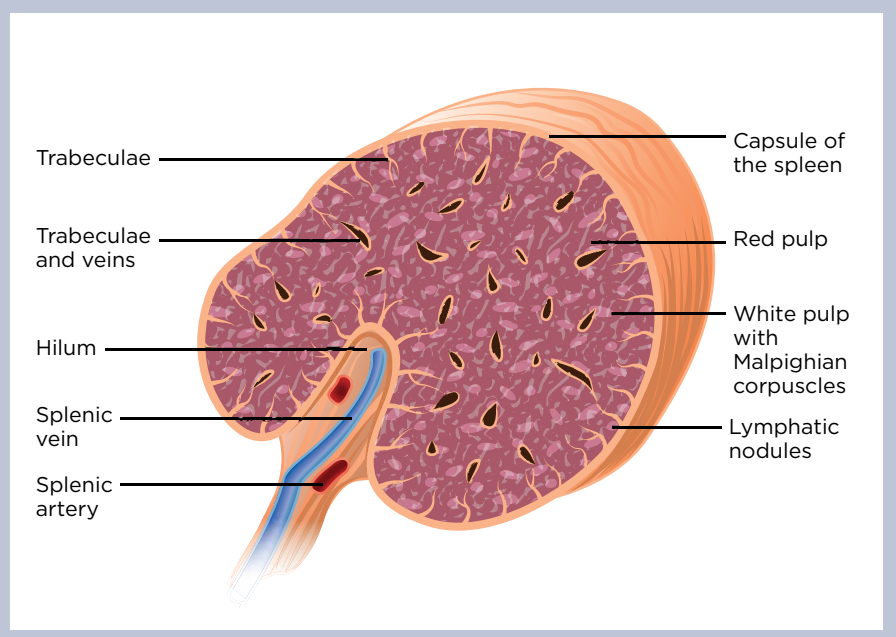
### Clinical significance

As the spleen is the largest collection of lymphoid tissue in the body, infections that cause white blood cell proliferation and antigenic stimulation may cause germinal centres in the organ to expand, resulting in its enlargement (splenomegaly). This happens in many diseases – for example, malaria, cirrhosis and leukaemia. The spleen is not usually palpable, but an enlarged spleen is palpable during deep inspiration. Enlargement may also be caused by any obstruction in blood flow, for example in the hepatic portal vein.

### Removal

The anatomical position of the spleen coincides with the left tenth rib. Given its proximity to the abdominal wall, it is one of the most commonly injured organs in blunt abdominal trauma. The spleen is a fragile organ and, due to its highly vascularised nature, any injury causing rupture will rapidly lead to severe intraperitoneal haemorrhage; death may result due to massive blood loss and shock.

Fig 3. Cross-section of the spleen



A moderate splenic injury may be managed conservatively, but an extensively burst or ruptured spleen may be treated by complete and prompt removal (splenectomy). However, current data supports successful non-operative management of many traumatic splenic injuries, with the intention of reducing the need for complete removal (Armstrong et al, 2019).

Patients being treated for certain malignant diseases may also require a partial or total splenectomy and, although other structures such as the bone marrow and liver can take over some of the functions that are usually carried out by the spleen, such patients may be at increased risk of infection. With an overwhelming post-splenectomy infection, there is also an increased risk of sepsis, which is associated with significant morbidity and mortality. Infection is usually with encapsulated pathogens, including *Streptococcus pneumoniae*, *Haemophilus influenzae* and *Neisseria meningitidis*. Clinical guidelines to help reduce the risk of infection advocate education about infection prevention, vaccination and antibiotic prophylaxis (Arnott et al, 2018).

### Lymph nodes

Lymph nodes vary in size and shape, but are typically bean-shaped structures found clustered at specific locations throughout the body. Although their size varies, each node has a characteristic internal structure (Fig 4).

The central portions of the lymph node are essential to its function; here, there are large numbers of fixed macrophages, which

phagocytose foreign material such as bacteria on contact, and populations of B- and T-cells. Lymph nodes are crucial to most antibody-mediated immune responses: when the phagocytic macrophages trap pathogenic material, that material is presented to the lymphocytes so antibodies can be generated.

Each lymph node is supplied by one or more afferent lymphatic vessels, which deliver crude, unmodified lymph directly from neighbouring tissues. A healthy, fully functioning node removes the majority of pathogens from the lymph before the fluid leaves via one or more efferent lymphatic vessels. In addition to its lymphatic supply, each lymph node is supplied with blood via a small artery; the artery delivers a variety of leucocytes, which populate the inner regions of the node.

When infection is present, the lymph nodes become increasingly metabolically active and their oxygen requirements increase. A small vein carries deoxygenated blood away from each node and returns it to the major veins. In times of infection, this venous blood may carry a variety of chemical messengers (cytokines) that are produced by the resident leucocytes in the nodes. These cytokines act as general warning signals, alerting the body to the potential threat and activating a variety of specific immune reactions.

### Structure

The structure of a lymph node is not unlike that of the spleen. Each lymph node is divided into several regions:



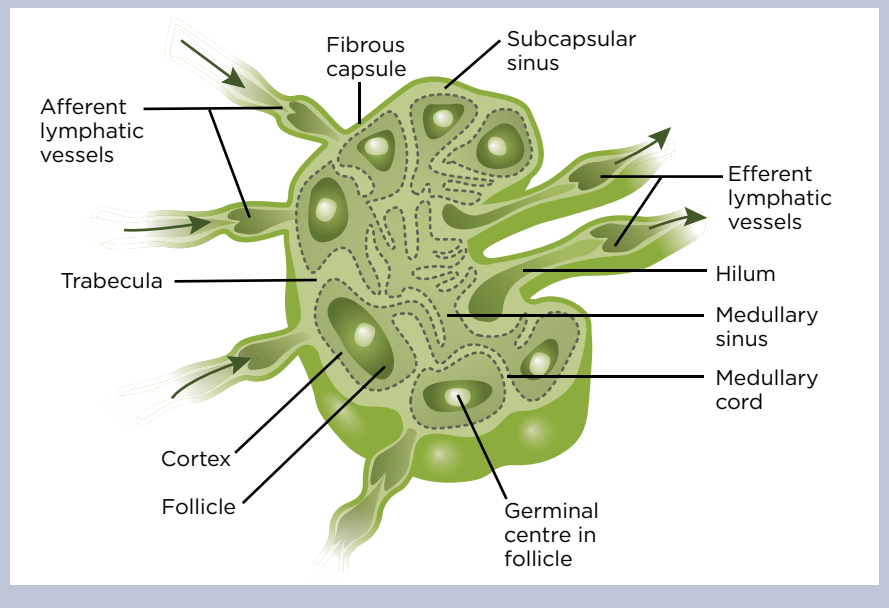
**“Swollen lymph nodes and a fever are sure signs that the body is mounting an effective immune response against an offending pathogen”**

- Fibrous capsule – this forms a protective outer sheath and has trabeculae that extend periodically into the node, subdividing it into small compartments;
- Outer cortex (nodular cortex) – just inside the capsular margin, this consists of numerous follicles that are rich in B-cells. When pathogens are present, these follicles expand to reveal prominent germinal centres containing actively dividing, antibody-secreting B-cells;
- Inner cortex (paracortex) – this is just below the outer cortex and is particularly rich in T-cells, which also continually circulate throughout most other regions of the node;
- Medulla – the central inner portion of the node that contains large numbers of fixed phagocytic macrophages. These continually monitor the lymph for potentially pathogenic foreign material (a process known as immunosurveillance), which they phagocytose on contact.

**Clinical significance**

During infection, antibody-producing B-cells begin to proliferate in the germinal centres, causing the affected lymph nodes to enlarge and become palpable and tender. Some of the cytokines released are pyrogenic (meaning they cause fever) and act directly on the thermoregulatory centre in the hypothalamus to increase body temperature. As the majority of human pathogens divide optimally at around 37°C, this

Fig 4. Internal structure of a lymph node



increase in body temperature serves to slow down bacterial replication, allowing the infection to be dealt with more efficiently by the immune system. Swollen lymph nodes and a fever are both sure signs that the body is mounting an effective immune response against the offending pathogen; this will be discussed in more detail in part 3 of this series.

**Other lymphatic components**

Other types of lymphatic tissue also exist. Mucosa-associated lymphoid tissue (MALT) is positioned to protect the respiratory and gastrointestinal tracts from invasion by microbes. The following are made up of MALT:

- Gut-associated lymphoid tissue;
- Bronchus-associated lymphoid tissue;
- The palatine, lingual and pharyngeal tonsils.

The tonsils are aggregates of lymphatic tissue strategically located to prevent foreign material and pathogens from entering the body. The palatine tonsils are in the pharynx, the lingual tonsils in the oral cavity and the pharyngeal tonsils (adenoids) are at the back of the nasal cavity; as a result of this, the tonsils themselves are at high risk of infection and inflammation (tonsillitis). This will also be discussed further in part 3. **NT**

**References**

Armstrong RA et al (2019) Successful non-operative management of haemodynamically unstable traumatic splenic injuries: 4-year case series in a UK major trauma centre. *European Journal of Trauma and Emergency Surgery*; 45: 5, 933-938.  
Arnott A et al (2018) A registry for patients with

asplenia/hyposplenism reduces the risk of infections with encapsulated organisms. *Clinical Infectious Diseases*; 67: 4, 557-561.  
Baković D et al (2005) Effect of human splenic contraction on variation in circulating blood cell counts. *Clinical and Experimental Pharmacology and Physiology*; 32: 11, 944-951.  
Bilder G (2016) *Human Biological Aggins: From Macromolecules to Organ Systems*. Wiley.  
Garnitschnig L et al (2020) Postprandial dynamics of splenic volume in healthy volunteers. *Physiological Reports*; 8: 2, e14319.  
Gujar S et al (2017) A cadaveric study of human spleen and its clinical significance. *National Journal of Clinical Anatomy*; 6: 1, 35-41.  
Mańkiewicz A, Dziedzic M (2012) Bone marrow reconversion: imaging of physiological changes in bone marrow. *Polish Journal of Radiology*; 77: 4, 45-50.  
Pivkin IV et al (2016) Biomechanics of red blood cells in human spleen and consequences for physiology and disease. *Proceedings of the National Academy of Sciences of the United States of America*; 113: 28, 7804-7809.  
Severa M et al (2019) Thymosins in multiple sclerosis and its experimental models: moving from basic to clinical application. *Multiple Sclerosis and Related Disorders*; 27: 52-60.  
Sherer Y et al (1999) The dual relationship between thymectomy and autoimmunity: the kaleidoscope of autoimmune disease. In: Paul S (ed) *Autoimmune Reactions*. Contemporary Immunology. Totowa, NJ: Humana Press.  
Stewart IB, McKenzie DC (2002) The human spleen during physiological stress. *Sports Medicine*; 32: 6, 361-369.

**CLINICAL SERIES** **Lymphatic system series**

<b>Part 1:</b> Structure, function and oedema	Oct
<b>Part 2:</b> Lymphatic organs	Nov
<b>Part 3:</b> Immunity	Dec
<b>Part 4:</b> Allergies, anaphylaxis and anaphylactic shock	Jan 2021
<b>Part 5:</b> Vaccinations and immunological memory	Feb
<b>Part 6:</b> Immunotherapies	Mar



**Nursing Times  
Self-assessment  
online**

Test your knowledge with Nursing Times Self-assessment after reading this article. If you score 80% or more, you will receive a personalised certificate that you can download and store in your NT Portfolio as CPD or revalidation evidence.

To take the test, go to:  
[nursingtimes.net/NTSALymphatics](http://nursingtimes.net/NTSALymphatics)