

In this article...

- Role of the jejunum and ileum in chemical digestion and absorption of nutrients
- Nutrient absorption from the small intestine to the bloodstream via the villi
- Processes of segmentation and peristalsis

Gastrointestinal tract 4: anatomy and role of the jejunum and ileum

Key points

The small intestine comprises the duodenum, jejunum and ileum

The jejunum and ileum finish chemical digestion and absorb most of the nutrients

Folds and projections in the small intestine's wall increase the surface area for absorption

Nutrients are transported across the gut wall into the bloodstream passively or actively, sometimes with the help of carriers

Peristalsis moves unabsorbed matter towards the large intestine through the ileocaecal valve

Authors Yamni Nigam is professor in biomedical science; John Knight is associate professor in biomedical science; Nikki Williams is associate professor in respiratory physiology; all at the College of Human and Health Sciences, Swansea University.

Abstract After its passage through the duodenum, where most chemical digestion takes place, chyme passes through the jejunum and ileum. Their main role is to ensure that the various molecules resulting from chemical digestion pass through the gut wall into the blood or lymph. This process of nutrient absorption is helped by the presence of folds and projections that hugely increase the surface area of the gut wall, and regular contractions of the rings of smooth muscle that move intestinal contents back and forth. This article, the fourth in a six-part series exploring the gastrointestinal tract, describes the anatomy and functions of the jejunum and ileum.

Citation Nigam Y et al (2019) Gastrointestinal tract 4: anatomy and role of the jejunum and ileum. *Nursing Times*; 115: 9, 41-44.

With the exception of ingestion, the small and large intestines carry out all the major functions of the digestive system. This is where the 'real business' of digestion takes place. The intestines take up most of the space in the abdominal cavity and constitute the greatest portion of the gastrointestinal (GI) tract in terms of mass and length. They receive their blood supply through the mesenteric artery.

The small intestine is about five times longer than the large intestine but has a smaller diameter (about 2.54cm versus 7.62cm), which is why it is called 'small'. It comprises the duodenum (25cm), jejunum (around 2.5m) and ileum (around 3.5m). Tethered to the posterior wall of the abdomen by the mesentery (an extension of the peritoneum), the entire convolution of the small intestine lies loosely in the abdominal cavity, framed by the colon (Fig 1). Its folds and the projections in its lining create an enormous surface area of approximately 200m² – more than 100

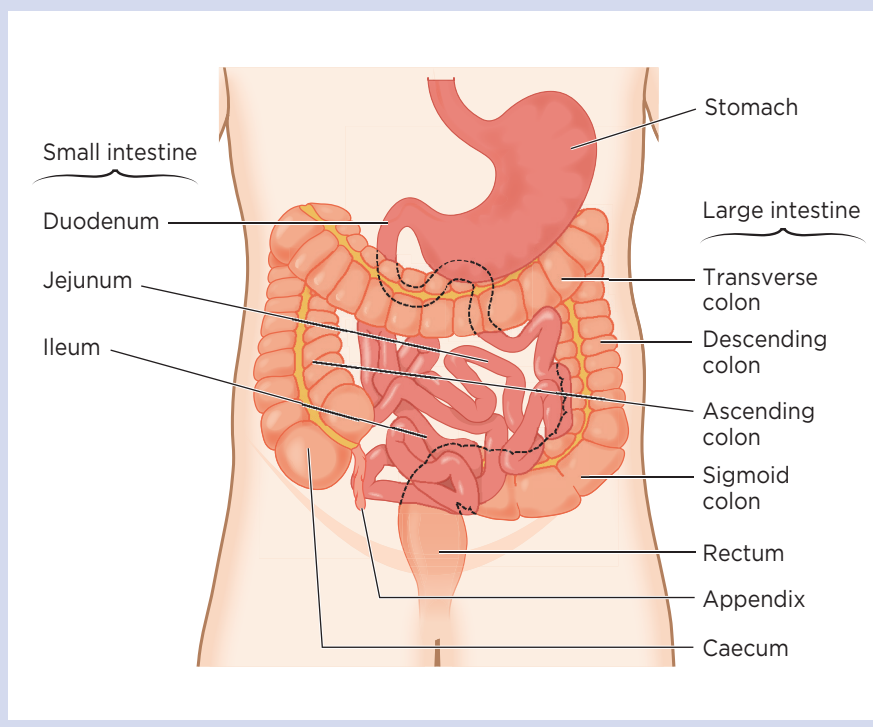
times the surface area of the skin – which is essential for the absorption of nutrients (Wilson, 2008).

The anatomy and function of the duodenum, the first part of the small intestine, is described in part 3 of this series on the GI tract. Having received acidic chyme from the stomach, the duodenum completes a large part of the process of chemical digestion, liberating small molecules from ingested food (see part 3). Once this is done, the jejunum and ileum mainly assume the role of absorbing these molecules (amino acids, monosaccharides and lipids), which pass into the bloodstream to be used by the body. This article, part 4 of the series, describes the anatomy and functions of the jejunum and ileum.

Anatomy of the jejunum

The jejunum makes up two-fifths of the total length of the small intestine and is about 0.9m in length. It starts at the duodenojejunal flexure and ends at the ileum. There is no clear border between the jejunum and the ileum. Histologically, the

Fig 1. Anatomy of the small and large intestines



The venules allow glucose and amino acids to be absorbed directly into the bloodstream, while products from the breakdown of lipids (fatty acids and glycerol) are absorbed into the lymphatic system via the lacteals.

Microvilli

The mucosal epithelial cells (Fig 3) have thin, hair-like extensions about 1µm (0.001mm) in length, jutting out into the intestinal lumen. These tiny projections are known as microvilli and there are approximately 200 million of them per 1mm². They expand the surface area available for nutrient absorption by another 20 times. Microscopically, they appear as a mass of bristles and are, therefore, termed the brush border. Fixed to the surface of the microvilli are a series of enzymes that finish chemical digestion.

Anatomy of the ileum

The ileum is the longest part of the small intestine, making up about three-fifths of its total length. It is thicker and more vascular than the jejunum, and the circular folds are less dense and more separated (Keuchel et al, 2013). At the distal end, the ileum is separated from the large intestine by the ileocaecal valve, a sphincter formed by the circular muscle layers of the ileum and caecum, and controlled by nerves and hormones. The ileocaecal valve prevents reflux of the

jejunum differs from the rest of the small intestine by the absence of Brunner's glands (which are present in the duodenum – see part 3) and Peyer's patches (which are present in the ileum – see part 1 and below).

A vast surface area is a prerequisite for the optimal absorption of nutrients, so the wall of the jejunum contains the following features that increase its surface area:

- Circular folds;
- Villi;
- Microvilli.

These features are also found, albeit with slight differences, in the ileum.

Circular folds

Macroscopically noticeable are the numerous circular folds (or valves of Kerckring) running parallel to each other in the mucosa of the jejunum. These deep ridges in the mucosal lining triple the surface area of the absorptive mucosa in the intestinal wall. They also slow down the flow of chyme, as their shape causes it to travel in a spiral fashion rather than moving down the GI tract in a straight line (Welcome, 2018). This slowing down provides more time for nutrients to be absorbed.

Villi

Located in the circular folds and measuring 0.5-1mm in length, finger-like projections known as villi extend into the

intestinal lumen (Fig 2), multiplying by 10 the surface area available for nutrient absorption. Each villus contains a:

- Capillary bed – comprising an arteriole and a venule;
- Lymphatic capillary – central lacteal (Fig 3).

Fig 2. Villi in intestinal mucosal lining

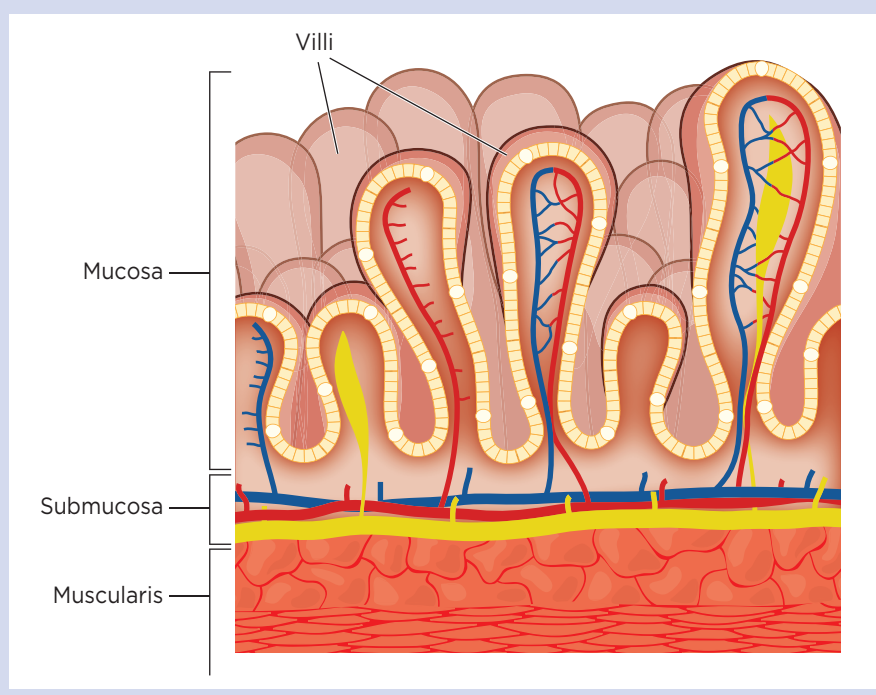
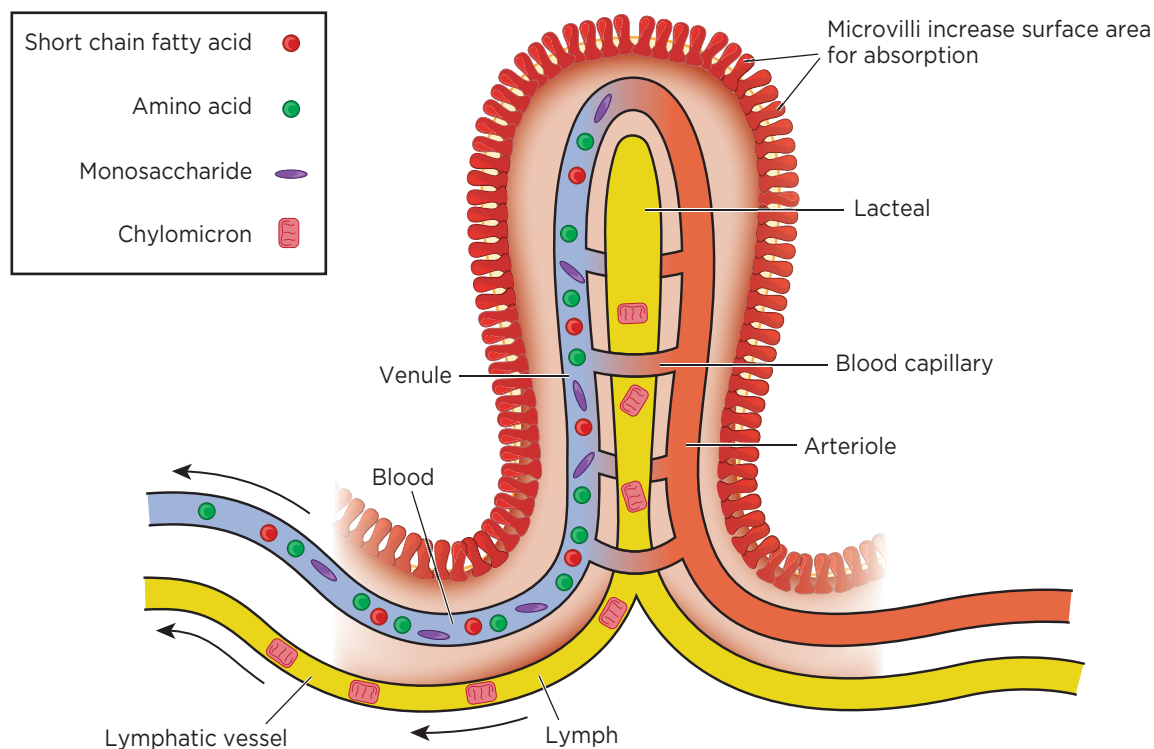


Fig 3. Longitudinal view of a villus



bacteria-rich content from the large intestine into the small intestine.

The ileum is rich in immune tissue (lymphoid follicles). A characteristic feature is Peyer's patches, found lying in its mucosa, which are an important part of gut-associated lymphoid tissue. One Peyer's patch is around 2-5cm long and consists of around 300 aggregated lymphoid follicles. These are concentrated in the distal ileum and serve to keep bacteria from entering the bloodstream.

Peyer's patches are most prominent in young people and become less distinct with age, which reflects the age-related reduction in activity of the gut's immune system.

Digestion and absorption

The duodenum accomplishes a good deal of chemical digestion, as well as a small amount of nutrient absorption (see part 3); the main function of the jejunum and ileum is to finish chemical digestion (enzymatic cleavage of nutrients) and absorb these nutrients along with water and vitamins. The brush border of the small intestine contains enzymes that complete the process of chemical digestion. Table 1 lists these enzymes and their roles.

"The small and large intestines carry out all the major functions of the digestive system"

The rings of smooth muscle in the wall of the small intestine repeatedly contract and relax in a process called segmentation. This moves intestinal contents back and forth. Segmentation distends the small intestine but does not drive chyme through the tract; instead, it mixes it with digestive juices and then pushes it against the mucosa to allow nutrient absorption.

Each day, approximately 8L of water (from dietary ingestion as well as GI tract secretions and juices, including saliva), several hundred grams of carbohydrates, $\geq 100\text{g}$ of fat, 50-100g of amino acids and 50-100g of salt ions pass through the wall of the small intestine and into the blood (Hall, 2011).

The transport of nutrients across the membranes of the intestinal epithelial cells into the villi, and subsequently into blood capillaries and lacteals, occurs either passively or actively. Passive transport requires no energy and involves the diffusion of simple molecules along a

concentration gradient – movement from an area where they are in high concentration to one where they are in lower concentration – in this case, the blood. Water and some vitamins can cross the gut wall passively. Active transport requires energy to pull molecules out of the intestinal lumen against a concentration gradient. In addition, certain molecules – such as glucose, amino acids and vitamin B12 – have their own carriers or transporters, which they use to 'piggyback' across the gut wall into the bloodstream.

Carbohydrates

Digested carbohydrates enter the blood capillaries irrigating each villus. Almost all ingested carbohydrates are absorbed as monosaccharides, 80% of which are glucose. Glucose is actively absorbed via a co-transport mechanism using sodium ions as carriers. Other absorbable monosaccharides include galactose from milk and fructose from fruit.

Amino acids

Most products of protein digestion (amino acids) are also absorbed through an active co-transport mechanism with sodium ions and enter the blood capillary system

of each villus. They then travel to the liver via the hepatic portal vein.

Fats

Digested fats mingle with bile salts, which ferry them to the mucosa where they are coated with lipoproteins and aggregated into small molecules called chylomicrons, which are taken into the central lacteals of the villi. They travel with lymph to the thoracic duct, where they enter the blood supply. If there is malabsorption of fats, these pass into the large intestine, where they form pale, oily, foul-smelling stools (steatorrhoea – see part 3). When that happens, certain fat-soluble vitamins (A, D, E and K) may also not be absorbed, potentially leading to deficiencies.

QUICK FACT **200m²**
Approximate surface area of the intestines available for nutrient absorption

Vitamin B complex

The vitamin B complex encompasses eight water-soluble vitamins that are essential for key functions of the body, including red blood cell formation, maintenance of healthy hair and nails, and healthy functioning of the brain and heart. These eight vitamins are: B1 (thiamine), B2 (riboflavin), B3 (niacin), B5 (pantothenic acid), B6 (pyridoxine), B7 (biotin), B9 (folate) and B12 (cobalamin).

Vitamin B1. Essential for metabolism, vitamin B1 also plays a role in healthy nerve conduction and muscle contraction. It is found in fortified foods such as bread and cereals, but also in eggs, fish, nuts, legumes and certain meats (Wiley and Gupta, 2019). Vitamin B1 deficiency is common in people who have a poor diet (for example, homeless people) and can cause a range of disorders including beriberi. In some cases, vitamin B1 deficiency can be caused by long-term, heavy alcohol intake, which eventually impairs the body's ability to absorb the vitamin. Vitamin B1 deficiency caused by alcohol can result in Wernicke's encephalopathy or Korsakoff's psychosis.

Vitamin B12. This vitamin is essential for red blood cell development, normal functioning of the nervous system, cell metabolism and DNA synthesis. The richest natural sources of vitamin B12 are liver and kidney, but it is also present in meat, fish, dairy products, eggs and shellfish.

Table 1. Brush border enzymes of the small intestine and their role in chemical digestion

Enzyme	Activity
Maltase	Digests the disaccharide maltose into two molecules of glucose
Sucrase	Digests the disaccharide sucrose into glucose and fructose
Lactase	Digests the disaccharide lactose into glucose and galactose
Intestinal lipase	Digests fats into fatty acids and glycerol
Intestinal peptidases	Completes protein digestion by digesting peptides into their amino acid components

Vitamin B12 is liberated from ingested food in the acid milieu of the stomach. In the duodenum, it binds with intrinsic factor produced by the gastric parietal cells (see part 2); it is only in that bound form that it can be absorbed (Moll and Davis, 2017). Absorption occurs in the terminal portion of the ileum, where vitamin B12 attaches to specific membrane receptors located on absorptive cells (enterocytes) at the bottom of the pits between the microvilli (Schjøsby, 1989). To leave the enterocytes and enter the bloodstream, the vitamin must then bind to a carrier protein, transcobalamin II.

A common cause of vitamin B12 deficiency is the destruction of gastric parietal cells by autoantibodies, which severely reduces gastric acid production by the stomach and leads to a condition known as pernicious anaemia (see part 2). Vitamin B12 deficiency should not be ignored. If individuals who are deficient do not receive injections of the vitamin they may experience severe negative consequences, including dementia.

Movement towards the large intestine

Digestive activity in the stomach provokes the gastroileal reflex, which stimulates peristalsis to push contents along the ileum and the colon. The reflex ensures that the content of one meal is completely emptied from both the stomach and the small intestine before the next meal is eaten. It can take up to five hours for all chyme to leave the small intestine (Young et al, 2014).

When most of the chyme has been absorbed, the walls of the small intestine become less distended and segmentation gives way to peristalsis, which helps move unabsorbed matter along towards the large intestine. Peristalsis works a little like squeezing toothpaste along and out of a tube. With each repeated peristaltic contraction, chyme and waste slowly move down the small intestine. When motility in

the ileum increases, the ileocaecal valve relaxes, allowing food residue to enter the large intestine at the caecum. **NT**

● Part 5 of our six-part series on the anatomy and physiology of the gastrointestinal tract will describe the anatomy and functions of the large intestine, as well as common pathologies of the small and large intestines.

References

Hall JE (2011) Digestion and absorption in the gastrointestinal tract. In: *Guyton and Hall Textbook of Medical Physiology*. Philadelphia, PA: Saunders.
 Keuchel M et al (2013) Normal small bowel. *Video Journal and Encyclopedia of GI Endoscopy*; 1: 1, 261-263.
 Moll R, Davis B (2017) Iron, vitamin B12 and folate. *Medicine*; 45: 4, 198-203.
 Schjøsby H (1989) Vitamin B12 absorption and malabsorption. *Gut*; 30: 12, 1686-1691.
 Welcome MO (2018) Structural and functional organization of the gastrointestinal tract. In: *Gastrointestinal Physiology: Development, Principles and Mechanisms of Regulation*. Cham: Springer International Publishing.
 Wiley KD, Gupta M (2019) *Vitamin B1 Thiamine Deficiency (Beriberi)*. Treasure Island, FL: StatPearls. [Bit.ly/StatPearlsThiamine](https://bit.ly/StatPearlsThiamine)
 Wilson M (2008) The indigenous microbiota of the gastrointestinal tract. In: *Bacteriology of Humans: An Ecological Perspective*. Oxford: Wiley-Blackwell.
 Young KA et al (2014) The small and large intestines. In: *Anatomy and Physiology*. Houston, TX: OpenStax College.



For more on this topic online

- Anatomy and physiology of ageing 3: the digestive system
[Bit.ly/NTDigestiveSOL](https://bit.ly/NTDigestiveSOL)

CLINICAL SERIES

Gastrointestinal tract series

- Part 1:** The mouth and oesophagus Jun
[Bit.ly/NTGITract1](https://bit.ly/NTGITract1)
- Part 2:** The stomach Jul
[Bit.ly/NTGITract2](https://bit.ly/NTGITract2)
- Part 3:** The duodenum, liver and pancreas Aug
[Bit.ly/NTGITract3](https://bit.ly/NTGITract3)
- Part 4:** The jejunum and ileum Sep
- Part 5:** The large intestine Oct
- Part 6:** Gut microbes Nov