



Swansea University  
Prifysgol Abertawe



## Cronfa - Swansea University Open Access Repository

---

This is an author produced version of a paper published in:  
*Journal of Craniovertebral Junction and Spine*

Cronfa URL for this paper:  
<http://cronfa.swan.ac.uk/Record/cronfa39519>

---

### Paper:

Boktor, J., Pockett, R. & Verghese, N. (2018). The expandable Transforaminal Lumbar Interbody Fusion - 2 year follow up. *Journal of Craniovertebral Junction and Spine*, 9(1), 50-55.  
[http://dx.doi.org/10.4103/jcvjs.JCVJS\\_21\\_18](http://dx.doi.org/10.4103/jcvjs.JCVJS_21_18)

This is an open access journal, and articles are distributed under the terms of the Creative Commons Attribution-NonCommercial-ShareAlike 4.0 License.


---

This item is brought to you by Swansea University. Any person downloading material is agreeing to abide by the terms of the repository licence. Copies of full text items may be used or reproduced in any format or medium, without prior permission for personal research or study, educational or non-commercial purposes only. The copyright for any work remains with the original author unless otherwise specified. The full-text must not be sold in any format or medium without the formal permission of the copyright holder.

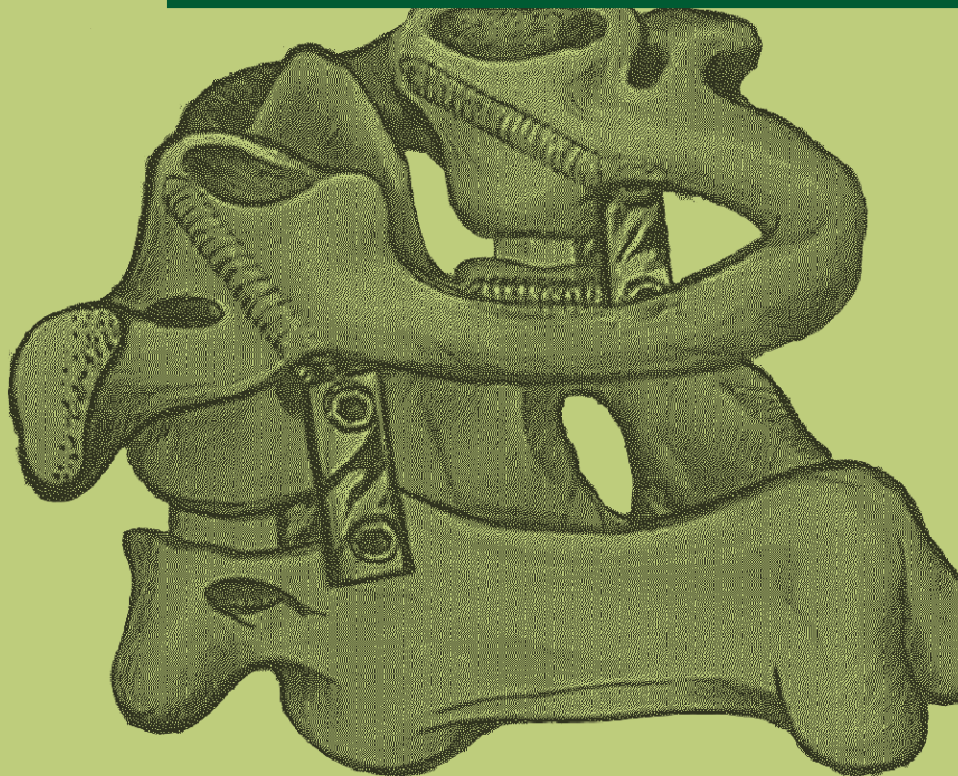Permission for multiple reproductions should be obtained from the original author.

Authors are personally responsible for adhering to copyright and publisher restrictions when uploading content to the repository.

<http://www.swansea.ac.uk/library/researchsupport/ris-support/>



# Journal of Craniovertebral Junction & Spine



[www.jcvjs.com](http://www.jcvjs.com)



January-March 2018 / Volume 9 / Issue 1

## The expandable transforaminal lumbar interbody fusion – Two years follow-up

### ABSTRACT

**Study Design:** This was a retrospective, observational study.

**Objectives:** We hypothesize that the expandable transforaminal lumbar interbody fusion (TLIF) cage achieves satisfactory clinical outcomes while allowing for safe placement, improvement, and maintenance of foraminal and disc dimensions at 24 months postsurgery with low risk of cage migration, subsidence, and nerve injury.

**Methods:** TLIF with expandable cages was performed in 54 patients (62 levels) over a 24-month-period using open midline or minimally invasive surgery techniques with placement of Globus Caliber, Rise, or Altera expandable cages. All patients underwent clinical and radiological assessment at 6 weeks, 6 months, 1, and 2 years postoperatively. Clinical outcome was measured by Oswestry disability index (ODI), visual analog pain score for both back and leg (visual analog scores [VASs]). Radiological assessment was done by X-ray standing lateral position.

**Results:** There were significant clinical improvements in ODI, VAS leg, and VAS back at all postoperative time points. Disc height, foraminal height, focal Cobb angle, and global Cobb angle were significantly increased and maintained at all time points for 24 months ( $P < 0.001$ ). Dural tear occurred in one patient (1.9%). There were neither intra- or postoperative neurological complications nor cage subsidence nor migration.

**Conclusions:** These preliminary results indicate that the use of an expandable interbody cage achieves good clinical outcomes by improving and maintaining foraminal dimensions and disc height with minimal complication rate.

**Keywords:** Back pain, expandable interbody cage, interbody fusion, transforaminal lumbar interbody fusion

### INTRODUCTION

Posterior lumbar fusion (PLF) is a common surgical method of treating patients with spinal back and leg pain secondary to instability and stenosis. If performed with interbody grafting, it may improve fusions rates, restoration of spinal canal dimensions, and lumbar lordosis which in turn may improve pain and clinical outcomes.<sup>[1]</sup> Interbody grafting can be performed through posterior lumbar interbody fusion (PLIF), lateral lumbar interbody fusion (LLIF), and anterior lumbar interbody fusion (ALIF) approaches.<sup>[2]</sup> Transforaminal approaches transforaminal lumbar interbody fusion (TLIF) has the benefit of being placed through a single posterior approach through a unilateral corridor and not requiring an approach close to the vascular structures. However, due to the narrow neural corridor, it is associated with an increased risk of dural

injury<sup>[3]</sup> and compromised cage size, leading to increased risk of cage subsidence.<sup>[4]</sup>

The more recently developed expandable TLIF cages have the potential advantages of less neurological injury as well as less impaction needed while inserting the cage. Furthermore, the more line to line fit of the cage after expansion may allow for greater indirect decompression as well as less risk of cage migration and subsidence. The counterargument is that

#### JOSEPH GAMAL BOKTOR, RHYS D POCKETT<sup>1</sup>, NAVIN VERGHESE


Department of Spine, Morriston Hospital, <sup>1</sup>Swansea Centre for Health Economics, College of human and Health Sciences, Swansea University, Swansea, UK

**Address for correspondence:** Dr. Joseph Gamal Bektor, Spinal Fellow Morriston Hospital, Wales, UK.  
E-mail: jostawro@hotmail.com

This is an open access journal, and articles are distributed under the terms of the Creative Commons Attribution-NonCommercial-ShareAlike 4.0 License, which allows others to remix, tweak, and build upon the work non-commercially, as long as appropriate credit is given and the new creations are licensed under the identical terms.

**For reprints contact:** reprints@medknow.com

**How to cite this article:** Bektor JG, Pockett RD, Vergheese N. The expandable transforaminal lumbar interbody fusion – Two years follow-up. *J Craniovert Jun Spine* 2018;9:50-5.

Access this article online	
<b>Website:</b> www.jcvjs.com	<b>Quick Response Code</b> 
<b>DOI:</b> 10.4103/jcvjs.JCVJS_21_18	

the process of expansion may increase the risk of endplate damage and hence subsidence. Furthermore, the expansion may leave a void across which fusion may not occur and therefore may compromise fusion rates.

Despite over 100,000 expandable TLIF cages being implanted worldwide, this study to our knowledge is the largest 2-year follow-up single-surgeon series in one spine centre relating to the expandable TLIF. The objective of this study is to show that clinical outcomes and radiographic assessments improved postsurgery and that these improvements were maintained at 24 months postsurgery with minimal complication rate.

## METHODS

A total of 62 expandable cage TLIFs were undertaken in 54 patients by one surgeon at one spinal unit between December 2013 and December 2015. There were three types of expandable cage included in this study: Globus Caliber, Rise, or Altera. The minimum follow-up was 1 year clinically and radiologically, and the maximum follow-up was 3 years (average follow-up is 23.5 months). All patients underwent clinical and radiological assessment at 6 weeks, 6 months, 1 year, and 2 years postoperatively. The preoperative patients' demographics are summarized in Table 1.

The patients fulfilled the following criteria: persistent stenotic leg pain more than 6 months with failed conservative treatment; radiological evidence of foraminal stenosis and/or spondylolisthesis with presence of spinal canal stenosis; and complete medical records. Data were collected retrospectively, using the preoperative hospital admission sheets, operative notes, postoperative follow-up, outpatient clinic documentations, and the British Spine Registry. Neither Institutional Review Board approval nor other similar entity approval was needed.

**Table 1: Patients' demographics**

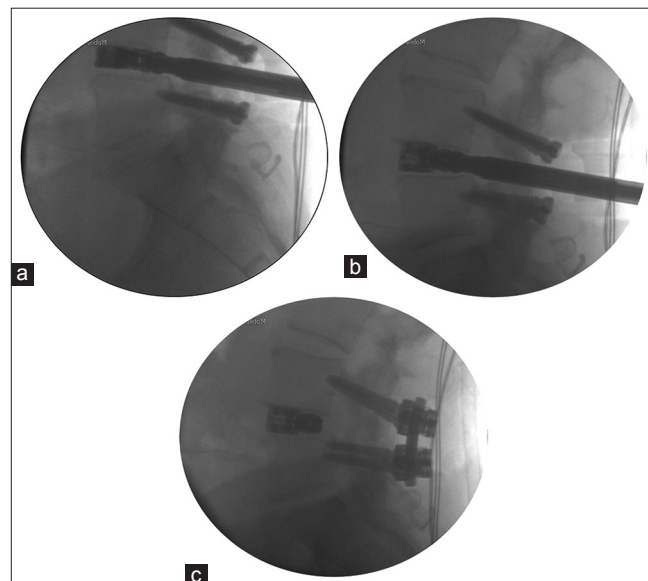
Demographic	n=54
Mean Age (StD, range)	56.1 (13.1, 33 to 85)
Gender (n, %)	
Male	24 (44.4)
Female	30 (55.6)
Smoker (n, %)	3 (5.6)
Diabetes (n, %)	5 (9.3)
Locations and levels (n, %)	
1 Level	46 (85.2)
2 Levels	8 (14.8)
L2/3	1 (1.6)
L3/4	5 (8.1)
L4/5	25 (40.3)
L5/S1	31 (50.0)

## Surgical procedure

Antibiotics are administered. The patient is positioned prone on a Jackson table with pads. Fluoroscopy image intensifier guidance is used as deemed appropriate. In the context of unilateral leg pain secondary to foraminal stenosis, a minimally invasive procedure is performed with percutaneous pedicle screws and screw-based retractor (Nuvasive MASTLIF) through which the facetectomy, exiting root decompression, and discectomy were performed. In the context of bilateral leg pain, an open or mini open TLIF is performed (Globus reverse pedicle or creo mediocortical trajectory screws, respectively). Following careful disc and endplate preparation, the size of the expandable cage is estimated. Local bone and demineralized bone matrix are placed anterior and lateral to the cage and within. Further posterolateral graft is also placed. Screws are connected with lordotic rods and judicious compression or distraction applied to achieve further lordosis or indirect decompression, respectively [Figure 1]. Wounds are closed in layers with suction drain *in situ*. All patients are mobilized day 1 postoperatively as comfort allowed. Drain and catheter are removed day 1 or 2 postoperatively. Postoperative standing X-rays are performed before discharge.

## Outcome measures

Clinical outcome was assessed using the Oswestry disability index (ODI) and visual analog score (VAS) for leg and back pain. Radiological assessment was performed blindly by one spinal fellow with 5-year-experience in spine surgery using intraobserver studies over 3-month period. The assessment included as follows: (1) Disc height ratio was calculated as the ratio between the disc height and the height of the superior vertebral body. Disc height was



**Figure 1: (a) Cage insertion, (b) Cage distraction, (c) Compression on screws to restore lordosis**

measured as perpendicular distance between the two cartilagenous endplates in the middle of the vertebra above. (2) Neuroforaminal height ratio was measured using the ratio with the vertebral body above. Neuroforaminal height was measured using line between the middle of the edge of superior and inferior pedicles. (3) Local Cobb angle (defined as the angle between the upper and lower edges of the intervertebral disc) and global Cobb angle (defined as the angle between the lower endplate of the L5 and the upper endplate of L1) [Figure 2a]. (4) Fusion rate was determined using Brantigan and Steffe criteria for interbody fusion<sup>[5]</sup> [Table 2] only solid radiographic fusion is counted as Fused. Probable fusion is considered not fused.

Standing Lateral view Dorsolumbar radiographs were performed immediately postoperatively and every 6 month after surgery for minimum of 2 years.

**Statistical analysis**

Paired samples *t*-tests were conducted to investigate whether there was a difference in patient reported pain between presurgery, 12 months postsurgery, and 24 months post-surgery, as identified using the ODI, VAS back, and VAS leg instruments. Paired samples *t*-tests were also conducted to investigate whether there was a difference in radiographic assessments (intervertebral disc height, neuroforaminal height, focal Cobb angle, and global Cobb angle between presurgery and 6, 12, and 24 months postsurgery, respectively).

**RESULTS**

The data collected from 54 patients (62 fusion levels as some patients had more than one level fusion) of surgically managed with expandable cages were analyzed [Table 3]. Nearly 68%

of patients had 2 years of follow-up. The average operative time was 132 min (126 for single level and 168 for two levels). The average blood loss was 167 ml (154 for single level and 241 for two levels). The average hospital stay was 4 days. The complications were as follows: dural tear was noted in one patient (1.9%). no deep infection was noted, no root injury, no persistent back pain, and neither cage migration nor subsidence were reported. There was no significant difference between the three cage types used. There was also no significant difference between MIS and open surgery.

**Clinical outcome**

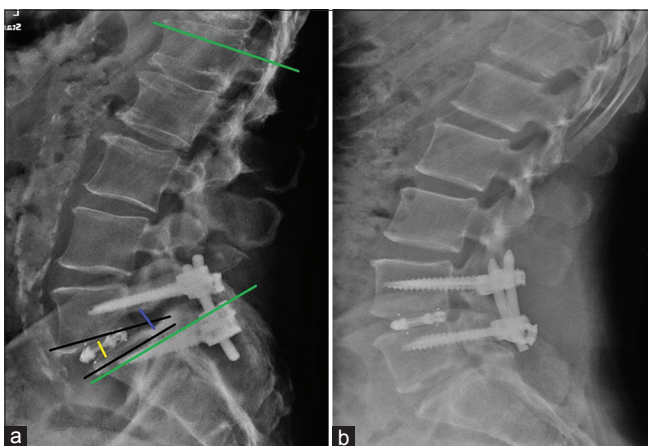
All patients had pain relief by the final follow-up. Mean ODI score improved significantly from 61.4 ± 17 preoperatively to 40 ± 18.8 at 12 months postoperatively, to 38.3 ± 22.1 at 24 months; *P* < 0.001 in all follow-ups [Figure 3]. Mean back pain VAS improved significantly from 7.7 ± 2.3 preoperatively to 4.7 ± 2.7 at 12 months postoperatively, to

**Table 2: Description of fusion by Brantigan & Steffee**

Fusion grade	Description
Obvious radiographic pseudoarthrosis:	Collapse of construct, loss of disc height, vertebral slip, broken screws or resorption of bone graft.
Probable radiographic pseudoarthrosis:	Visible gap or lucency >2mm in the fusion area.
Radiographic status uncertain:	A small visible gap with at least half of the graft area showing no lucency between the graft bone and vertebral bone
Probable Radiographic fusion:	Bone bridges the entire fusion area with at least the density originally achieved at surgery. There should be no lucency between the graft bone and vertebral bone.
Radiographic fusion:	The bone in the fusion area is more dense and more mature than originally achieved in surgery, there is no interface between the donor bone and vertebral bone ; a sclerotic line between the graft and vertebral bone indicates solid fusion. Other indicators of solid fusion is fusion of the facet joints and anterior progression of the graft in the disc

**Table 3: Intra & Postoperative clinical data**

Variables	Results
Operating Time	(mins) (StD, range)
All	132.3 (30.7, 75 to 210)
1 Level	126.0 (26.8, 75 to 200)
2 Levels	168.8 (27.0, 130 to 210)
Blood Loss	(mL) (StD, range)
All	167.4 (71.2, 100 to 350)
1 Level	154.6 (63.4, 100 to 350)
2 Levels	241.3 (72.0, 130 to 350)
Complications	(n, %)
Dural tear	1 (1.9)
Hospital Length of Stay	(days) (StD, range)
All	4.6 (2.2, 1 to 11)
1 Level	4.2 (2.1, 1 to 11)
2 Levels	6.6 (1.7, 4 to 8)



**Figure 2: (a) Measuring variable angles and neural dimensions: (1) Red line: neuroforaminal height. (2) Blue line: Disc height. (3) Yellow line: Focal and Global Cobb angle, (b) Follow-up X-ray**

4.6 ± 3.3 at 24 months;  $P < 0.001$  in all follow-ups [Figure 4]. Mean leg pain VAS decreased significantly from 7.8 ± 2.5 preoperatively to 3.5 ± 2.8 at 12 months postoperatively, to 3.7 ± 3.2 at 24 months;  $P < 0.001$  in all follow-ups [Figure 5].

### Radiological outcomes

Fusion rate was satisfactory, reaching 93% Grade 5 by Brantigan and Steffe classification by 12 months and 100% by 24 months. Radiological assessment from the 2-year follow-up in 37 patients (41 levels) was as follows: intervertebral disc heights changed from 8.8 ± 2.7 preoperatively to 14 ± 2.2 postoperatively to 13.9 ± 2.1 at 6 months follow-up, to 13.6 ± 2.2 at 1 year and 13.3 ± 2.6 at 2 years.  $P < 0.001$  in all follow-ups [Figure 5]. Neuroforaminal height changed from 17.4 ± 3.1 preoperatively to 21.3 ± 3 postoperatively to 20.6 ± 2.7 at 6 months postoperatively, to 20.3 ± 2.9 at 1 year and 19 ± 2.7 at 2 years.  $P < 0.001$  in all follow-ups [Figure 6]. Focal Cobb angle improved from 7 ± 4.5 preoperatively to 10.2 ± 4.1 postoperatively to 9.7 ± 3.8 at 6 months follow-up, to 9.7 ± 4.2 at 1 year and 7.3 ± 3.3 at 2 years.  $P < 0.001$  in all follow-ups [Figure 7]. Global Cobb angle improved from 42.2 ± 15.1 preoperatively to 49.4 ± 13.9 postoperatively, to 49.5 ± 13.9 at 6 months follow-up, to 48.9 ± 14.4 at 1 year and 45.4 ± 16 at 2 years;  $P < 0.001$  in all follow-up [Figure 8].

Radiological assessment for 37 patients (41 levels) preoperative and at 2 years showed also significant maintained improvement in disc height from 8.3 ± 3 to 13.3 ± 2.6, neuroforaminal height from 17 ± 3.4 to 19 ± 2.7, focal Cobb angle from 5.5 ± 4.3 to 7.3 ± 3.3, and global Cobb angle from 40.9 ± 15.7 to 45.4 ± 16.  $P < 0.001$  in all follow-ups [Table 4].

### DISCUSSION

Spinal leg pain may be as a result of disc and foraminal collapse compressing the exiting nerve root. In such circumstances, an uninstrumented decompression alone may not achieve the required root decompression to provide leg pain relief. Therefore, a fusion can be performed to restore the foraminal dimensions and achieve indirect decompression of the root with or without supplemental direct decompression. It is also frequently performed in the setting of instability and symptomatic spondylolisthesis.<sup>[1]</sup> Several types of lumbar fusion have been performed including PLF as well as interbody grafting options from posterior PLIF, ALIF, LLIF, and the transforaminal (TLIF) approaches.<sup>[2]</sup>

Interbody fusion for back pain was pioneered by Cloward in 1940, using tricortical iliac graft.<sup>[6]</sup> In 1985, Cloward claimed 87%–92% clinical success and 92% fusion success in his 40-year-experience.<sup>[7]</sup> In 1993, Brantigan and Steffee

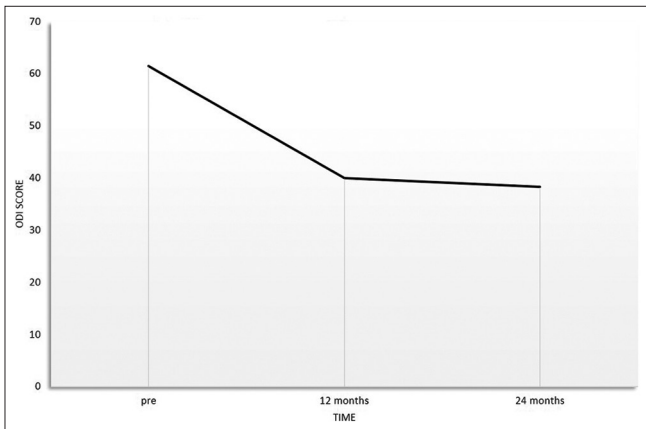


Figure 3: Mean Oswestry disability index changes over 24-month follow-up

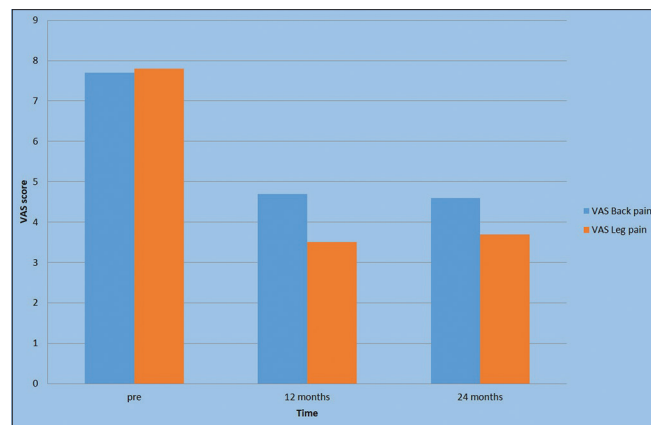


Figure 4: Mean visual analog score back pain and leg pain over 24-month follow-up

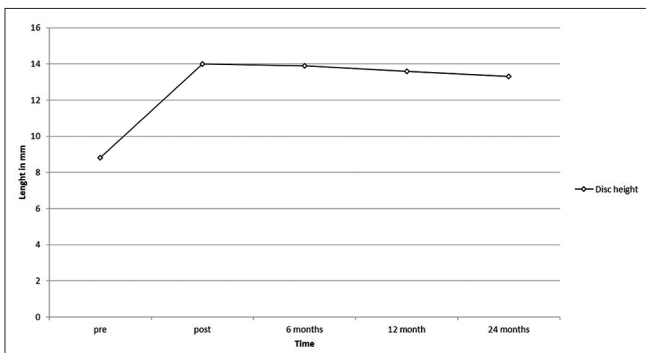


Figure 5: Disc height changes over 24 months

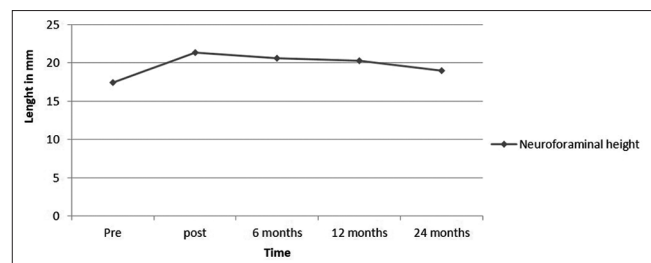


Figure 6: Neuroforaminal height changes over 24 months

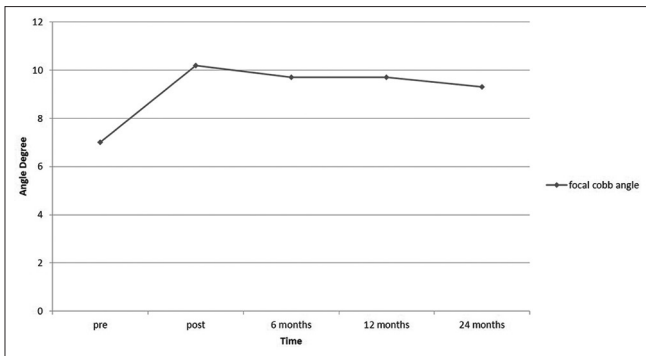


Figure 7: Focal Cobb angle changes over 24 months

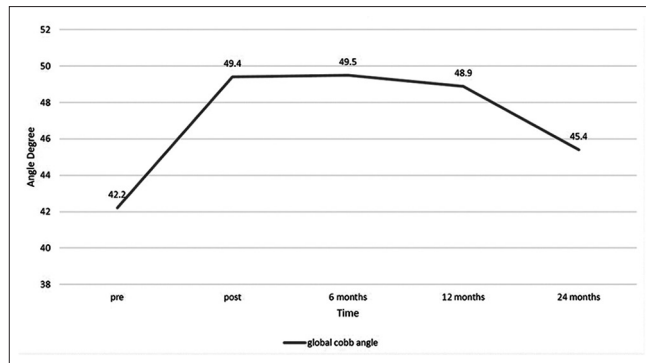


Figure 8: Global Cobb angle changes over 24 months

Table 4: Radiological outcome for 37 patients with 2 year follow up preoperatively and at 2 years.

	Mean (SD) Disc height	Mean (SD) Neuroforaminal height	Mean (SD) Focal cobb angle	Mean (SD) global cobb angle
Pre-operative	8.3 (3.0)	17.0 (3.4)	5.5 (4.3)	40.9 (15.7)
Post-Operative (24m)	13.3 (2.6) <i>P</i> <0.001 <sup>§</sup>	19.0 (2.7) <i>P</i> =0.001 <sup>§</sup>	7.3 (3.3) <i>P</i> =0.001 <sup>§</sup>	45.4 (16.0) <i>P</i> =0.001 <sup>§</sup>

developed the first interbody synthetic cage which was carbon-fiber-reinforced implant and achieved 100% fusion rate in 26 patients in 2-year follow-up.<sup>[5]</sup>

MIS with lumbar interbody fusion using an interbody cage was introduced in 2002 by Foley and Lefkowitz,<sup>[8]</sup> This surgery offered the advantages of the MIS techniques with less bleeding, less infection, and less postoperative pain; however, the radiological outcome was not statistically different from the open TLIF.<sup>[3,4,9-11]</sup>

In 2005, McAfee *et al.* published a retrospective study on radiological outcomes of static TLIF cages on 120 patients with spondylolisthesis with minimal follow-up 2 years. The results demonstrated that TLIF cages maintained an increase of disc height by 68%. Intraoperative complications included dural tear in seven patients (5.8%). Revision surgery was needed in three patients (2.5%), two due to deep infection (1.6%), and one complicated with cage migration (0.8%).<sup>[12]</sup>

In 2011, Rouben *et al.* analyzed retrospectively 169 patients treated by MIS static TLIF cages for back pain with an average follow-up of 49 months. There was a significant improvement in clinical outcome with a fusion rate of 96%. Complications were adjacent segment disease in three patients and pseudoarthrosis in one patient with a total of four patients requiring revision surgery (2.3%).<sup>[13]</sup>

In 2010, Aoki *et al.* noted cage migration within 3 months of static TLIF in a case series of 125 patients (3.2%). Two of

them had unilateral fixation. They explained this due to the presence of scoliotic curve and undersized cages.<sup>[14]</sup>

In 2015, Phan *et al.* systematically reviewed and compared ALIF versus TLIF including six electronic databases. The TLIF group showed dural tear incidence of 3.8%.<sup>[15]</sup>

In 2016, Kim *et al.* published a study about MIS expandable cage TLIF on 50 patients demonstrating maintenance of disc dimensions in single- and double-level primary fixation. There were no significant intraoperative or perioperative complications, dural tear, and infection reported. Postoperative radiographs showed no evidence of cage migration, subsidence, or collapse and suggested fusion at all operative levels by 12 months and 24 months (93%, 97%), respectively.<sup>[16]</sup> This study highlighted the potential benefits of the expandable cage with regard to reduced implantation-related complication rates. However, very few further studies exist in the literature.

Our study included 54 patients. There was minimally invasive and open surgery with clinical and radiological follow-up for 2 years. The results indicate a similar rate of fusion to static cage TLIFs, yet with low complication rate and hospital stay while restoring and maintaining the intervertebral and neuroforaminal height, and focal and global Cobb angle over 2-year follow-up. It is noted that focal Cobb angle remains static while Global Cobb angle was less maintained due to associated pathology in upper lumbar spine segments which is not related to the fusion and nonadjacent segment disease [Table 5].

**Limitation to the study**

It was performed retrospectively with lack of control group. Computerized tomography scanning would provide more accurate information regarding fusions rates but would subject the patient group to increased radiation which we felt unnecessary in patients with no clinical indication to be scanned.

**Table 5: Comparison between previous studies and current study regarding Interbody fusion with cage.**

Study Name & Date	Type of cage	No of patients	Follow up	Fusion Rate	Maintained disc height & neuroforaminal height	Complication
Cloward <i>et al.</i> 1940	Tricortical graft	40 years experience	N/A	92%	N/A	N/A
Brantigan 1993	Carbon fibre synthetic cage	26	2 years	100%	N/A	N/A
Mcaffe <i>et al</i> 2005	Static TLIF	120	2 years	N/A	Disc height maintained in 68%	Dural tear (5.8%) Deep infection (1.6%) Cage migration (0.8)
Rouben <i>et al</i> 2011	MIS Static TLIF	169	49 months	96%	N/A	Adjacent segment disease (1.7%) Pseudoarthrosis (0.6%)
Kim <i>et al</i> 2016	MIS expandable TLIF	50	2 years	97%	Improved & Maintained	Nil
Current study	Expandable TLIF (open & MIS)	54	2 years	100%	Improved & Maintained	Dural tear (1.9%)

## CONCLUSIONS

These preliminary results indicate that the use of an expandable interbody cage minimizes approach-related neural injury and achieves good clinical as well as radiological outcomes by improving and maintaining foraminal dimensions and disc height with no evidence of cage migration or subsidence in our series. We recommend longer term follow-up and a randomized controlled trial comparing expandable with static interbody cages.

## Financial support and sponsorship

Nil.

## Conflicts of interest

There are no conflicts of interest.

## REFERENCES

- Macki M, Bydon M, Weingart R, Sciubba D, Wolinsky JP, Gokaslan ZL, *et al.* Posterolateral fusion with interbody for lumbar spondylolisthesis is associated with less repeat surgery than posterolateral fusion alone. *Clin Neurol Neurosurg* 2015;138:117-23.
- Lee CK, Kopacz KJ. Lumbosacral: Posterior lumbar interbody fusion. In: Herkowitz HN, Garfin SR, Eismont FJ, Bell GR, Balderston RA, editors. *Rothman – Simeone The Spine*. Philadelphia: Elsevier; 2006. p. 350-60.
- Foley KT, Lefkowitz MA. Advances in minimally invasive spine surgery. *Clin Neurosurg* 2002;49:499-517.
- Villavicencio AT, Burneikiene S, Roeca CM, Nelson EL, Mason A. Minimally invasive versus open transforaminal lumbar interbody fusion. *Surg Neurol Int* 2010;1:12.
- Wang J, Zhou Y, Zhang ZF, Li CQ, Zheng WJ, Liu J, *et al.* Comparison of one-level minimally invasive and open transforaminal lumbar interbody fusion in degenerative and isthmic spondylolisthesis grades 1 and 2. *Eur Spine J* 2010;19:1780-4.
- Shunwu F, Xing Z, Fengdong Z, Xiangqian F. Minimally invasive transforaminal lumbar interbody fusion for the treatment of degenerative lumbar diseases. *Spine (Phila Pa 1976)* 2010;35:1615-20.
- Zhang K, Sun W, Zhao CQ, Li H, Ding W, Xie YZ, *et al.* Unilateral versus bilateral instrumented transforaminal lumbar interbody fusion in two-level degenerative lumbar disorders: A prospective randomised study. *Int Orthop* 2014;38:111-6.
- Hari A, Krishna M, Rajagandhi S, Rajakumar DV. Minimally invasive transforaminal lumbar interbody fusion-indications and clinical experience. *Neurol India* 2016;64:444-54.
- Brantigan JW, Steffee AD. A carbon fiber implant to aid interbody lumbar fusion. Two-year clinical results in the first 26 patients. *Spine (Phila Pa 1976)* 1993;18:2106-7.
- Cloward RB. The treatment of ruptured lumbar intervertebral discs by vertebral body fusion. I. Indications, operative technique, after care. *J Neurosurg* 1953;10:154-68.
- Cloward RB. Posterior lumbar interbody fusion updated. *Clin Orthop Relat Res* 1985;(193):16-9.
- McAfee PC, DeVine JG, Chaput CD, Prybis BG, Fedder IL, Cunningham BW, *et al.* The indications for interbody fusion cages in the treatment of spondylolisthesis: Analysis of 120 cases. *Spine (Phila Pa 1976)* 2005;30:S60-5.
- Rouben D, Casnellie M, Ferguson M. Long-term durability of minimal invasive posterior transforaminal lumbar interbody fusion: A clinical and radiographic follow-up. *J Spinal Disord Tech* 2011; 24:288-96.
- Aoki Y, Yamagata M, Nakajima F, Ikeda Y, Shimizu K, Yoshihara M, *et al.* Examining risk factors for posterior migration of fusion cages following transforaminal lumbar interbody fusion: A possible limitation of unilateral pedicle screw fixation. *J Neurosurg Spine* 2010;13:381-7.
- Phan K, Thayaparan GK, Mobbs RJ. Anterior lumbar interbody fusion versus transforaminal lumbar interbody fusion – Systematic review and meta-analysis. *Br J Neurosurg* 2015;29:705-11.
- Kim CW, Doerr TM, Luna IY, Joshua G, Shen SR, Fu X, *et al.* Minimally invasive transforaminal lumbar interbody fusion using expandable technology: A Clinical and radiographic analysis of 50 patients. *World Neurosurg* 2016;90:228-35.