



Swansea University  
Prifysgol Abertawe



## Cronfa - Swansea University Open Access Repository

---

This is an author produced version of a paper published in:

*Journal of Fetal Medicine*

Cronfa URL for this paper:

<http://cronfa.swan.ac.uk/Record/cronfa38518>

---

### **Paper:**

Balci, B., Goynumer, G., Biliciler-Denktaş, G., Babaoglu, K., Lewis, M. & Uzun, O. (2018). Fetal Cardiac Anomalies.

*Journal of Fetal Medicine*

<http://dx.doi.org/10.1007/s40556-018-0158-2>

---

This item is brought to you by Swansea University. Any person downloading material is agreeing to abide by the terms of the repository licence. Copies of full text items may be used or reproduced in any format or medium, without prior permission for personal research or study, educational or non-commercial purposes only. The copyright for any work remains with the original author unless otherwise specified. The full-text must not be sold in any format or medium without the formal permission of the copyright holder.

Permission for multiple reproductions should be obtained from the original author.

Authors are personally responsible for adhering to copyright and publisher restrictions when uploading content to the repository.

<http://www.swansea.ac.uk/library/researchsupport/ris-support/>

# Fetal Cardiac Anomalies

**Burcin Karamustafaoglu Balci, Gokhan Goynumer, Gurur Biliciler-Denktas, Kadir Babaoglu, Michael Lewis and Orhan Uzun**

1. Burcin Karamustafaoglu Balci, M.D., Ob/Gyn specialist, Istanbul Medeniyet University, Goztepe Training and Research Hospital, Istanbul, Turkey, [burcinkaramustafaoglu@yahoo.com](mailto:burcinkaramustafaoglu@yahoo.com)
2. Gokhan Goynumer, M.D., Prof. Dr., Düzce University, Faculty of Medicine, Duzce, Turkey, [goynumerego@gmail.com](mailto:goynumerego@gmail.com)
3. Gurur Biliciler-Denktas, MD, Associate Professor of Paediatric Cardiology, McGovern Medical School, UTHealth, Houston, TX, USA, [gurur.biliciler-denktas@uth.tmc.edu](mailto:gurur.biliciler-denktas@uth.tmc.edu)
4. Kadir Babaoglu, MD, Professor of Pediatric Cardiology. Kocaeli University, Medical Faculty. Izmit, Turkey, [babaogluk@yahoo.com](mailto:babaogluk@yahoo.com)
5. Michael Lewis, PhD, Professor of Sport Sciences and Cardiovascular Physiology. Swansea University, School of Engineering and Sport Sciences, Swansea, UK, [m.j.lewis@swansea.ac.uk](mailto:m.j.lewis@swansea.ac.uk)
6. Orhan Uzun, MD FRCP, Senior Lecturer Swansea University, School of Engineering and Sport Sciences; Consultant Paediatric Cardiologist, University Hospital of Wales, Heath Park, Cardiff, UK, [orhanuzun@hotmail.com](mailto:orhanuzun@hotmail.com)

## **Abstract**

This review is intended to give a practical guide to ultrasound recognition of the commonly observed fetal cardiac abnormalities and their key features on standard imaging planes during antenatal anomaly screening examinations. All information provided here, on the diagnosis and management of fetal cardiac anomalies, is based on the personal experiences of the authors and their expert reviews of the selected previously published studies.

**Key words: Fetal, cardiac, anomaly, screening, ultrasound**

**Address for correspondence:**

**Dr Orhan Uzun, MD FRCP**

**Consultant Paediatric Cardiologist**

**University Hospital of Wales**

**Heath Park, Cardiff CF14 4XW**

## **Introduction**

Congenital heart diseases (CHDs) can be classified clinically as severe, moderately severe or minor, based on the need for urgent palliative or corrective surgery at birth or during early infancy. Approximately one-half of CHDs are considered severe (or major) and require delivery at a tertiary cardiac/surgical center. Some severe CHDs (eg. Hypoplastic left heart syndrome, aortic atresia, mitral atresia, coarctation of the aorta, interrupted aortic arch, pulmonary atresia, transposition of the great arteries) are ductus arteriosus dependent conditions, in which the patency of the ductus arteriosus must be maintained with prostaglandin-E1 infusion in order to keep the child alive. Some of these anomalies (eg. hypoplastic left heart syndrome, aortic atresia, mitral atresia, tricuspid atresia, transposition of the great arteries, total anomalous pulmonary venous return) are also dependent on patency of the foramen ovale to maintain effective circulation. If such anomalies escape detection, antenatally or following birth, they can lead to cardiovascular collapse and sudden death after closure of the ductus arteriosus or the foramen ovale. Closure of the foramen ovale or the ductus arteriosus may be achieved during fetal life: in particular, restriction or closure of the ductus arteriosus may be provoked by drugs (such as indomethacin or ibuprofene).

In our opinion the classification of congenital heart defects presented in Table 1 is easy to remember and evaluate, and so it may be utilised by the screening workforce to increase the effectiveness of fetal cardiac anomaly screening programs. The frequency of congenital heart diseases and their genetic associations are summarized in Table 2. Table 3 outlines the best scanning planes and key features of congenital heart anomalies.

### **Details of specific defects:**

#### **Atrioventricular septal defect (AVSD)**

**Definition:** This anomaly comprises of an atrial and ventricular septal defect with a common atrioventricular valve (Figure 1). In the incomplete form, there is an ostium primum atrial septal defect and a cleft mitral valve with intact ventricular septum. In the complete form, an inlet ventricular septal defect is seen. This anomaly could be recognized from the four-chamber view by demonstrating the left and right inlet valves being at the same level (so-called 'loss of normal off-setting appearance') instead of their attachment point having different proximities to the base of the heart.

**Prenatal features and management:** Fetuses with this defect may be asymptomatic, depending on the size of the ventricular septal defect and the degree of atrioventricular valve insufficiency. Approximately 40-50% of fetuses with atrioventricular septal defect will have trisomy 21, 18 or 13, therefore amniocentesis would provide very useful counselling and prognostic information. Likewise, 40-50% of fetuses with trisomy 21 are likely to have atrioventricular septal defects. Atrioventricular septal defect may also coexist with pulmonary stenosis in 2-10% of cases. Isomerism may be seen in patients with AVSD and unbalanced ventricles.

**Postnatal management and outcome:** Neonates with atrioventricular septal defect might be totally asymptomatic or be only slightly cyanosed, and diagnosis in some cases may be overlooked. However, once the pulmonary vascular resistance drops those neonates with a large ventricular septal defect can develop respiratory symptoms, faltering growth and heart failure - generally beyond two weeks of age. Surgical repair of complete atrioventricular septal defect is usually undertaken before 6 months of age. After surgical repair, reasonable quality of life is expected but there is a 20% re-operation rate for leaky inlet valves. However, if there is disproportionate ventricular size (unbalanced atrioventricular septal defect) the postnatal outlook is less unfavorable as the corrective two ventricle repair cannot be achieved.

## **Ventricular septal defect (VSD)**

**Definition:** VSD is the most common congenital heart disease and accounts for 30% of all cardiac anomalies (1). VSD may be of muscular, membranous, subarterial or malalignment type.

**Prenatal features and management:** VSDs may be visualised in four-chamber, five-chamber and long-axis, and short-axis views (Figure 2). If the defect is small it can be missed in 2D alone thus adding colour flow and pulse wave Doppler can help to detect the lesion. The best way to confirm the diagnosis is to orient the ultrasound beam perpendicular to the ventricular septum, which can sometimes be challenging owing to unfavourable fetal position. The shunt should be in both directions. During the antenatal period, if the shunt is exclusively or predominantly right-to-left, there can be an obstruction in the right ventricular outflow tract (critical pulmonary stenosis or atresia) or mitral atresia with a patent left ventricular outflow tract. If the shunt is exclusively or predominantly left-to-right then critical or total obstruction of the left ventricular outflow tract should be excluded. Tricuspid atresia with a patent right ventricular outflow tract also exhibits a similar flow pattern. Inlet and membranous VSDs can be seen in the four-chamber view. Subarterial or outlet defects (as seen in tetralogy of Fallot, pulmonary atresia, truncus arteriosus and double outlet right ventricle) can be missed from the four-chamber view. The outlet VSDs are best viewed from the left ventricular long-axis or short-axis views.

The fetal clinical course is uneventful. Most small defects undergo spontaneous closure either before or after birth. Some commonly associated defects such as coarctation of the aorta, tetralogy of Fallot and truncus arteriosus should be ruled out. Amniocentesis should be offered in large defects owing to its high association with 22q11 deletion or trisomy syndromes. Small muscular defects are rarely associated with genetic abnormalities. Delivery does not need to

take place in a surgical centre if the ventricular septal defect is an isolated anomaly, regardless of its size. Postnatally, no special precaution is needed in the newborn other than routine paediatric and cardiac review and growth monitoring. Large ventricular septal defects might require medical treatment if they lead to faltering growth and heart failure in infancy.

**Postnatal management and outcome:** Surgical treatment of large VSD involves patch closure of the defect. Some defects may be suitable for device closure via transcatheter approach. Long term outcome after treatment is excellent.

### **Mitral atresia**

**Definition:** Mitral atresia is characterised by total obstruction to left ventricular inflow from the left atrium.

**Prenatal features and management:** Mitral atresia may be associated with pulmonary or aortic stenosis, transposition of the great arteries (TGA), coarctation of the aorta and VSD. The foramen ovale must remain open throughout pregnancy and following birth in all cases. If the foramen ovale becomes restrictive, fetal well-being can be threatened, therefore bi-weekly fetal cardiac surveillance until the end of pregnancy is required. Amniocentesis should be offered.

**Postnatal management and outcome:** Depending on the degree of pulmonary blood flow either an aorto-pulmonary shunt or pulmonary artery banding may be carried out during the neonatal period. This is followed by a superior caval vein-pulmonary artery shunt (Glenn) operation within 6 to 12 months and then finally the Fontan completion is performed (total cavopulmonary shunt) by the age of 5 years. Long term outlook of mitral atresia is determined by the success of the Fontan operation.

### **Tricuspid atresia**

**Definition:** This abnormality describes total obstruction to right ventricular inflow from the right atrium (Figure 3). There will be an absence of any opening motion of the tricuspid valve leaflets.

**Prenatal features and management:** Colour Doppler will fail to show any flow from the right atrium into the right ventricle. Tricuspid atresia can be associated with a VSD, pulmonary stenosis or atresia, transposition of the great arteries and congenitally-corrected transposition. Four-chamber view offers diagnostic clues but outflow tract view is also necessary to document any additional great artery abnormality, such as pulmonary stenosis or atresia. The foramen ovale must remain open throughout the pregnancy and after birth in all cases. If the foramen ovale becomes restrictive, fetal well-being can be threatened; therefore, bi-weekly fetal cardiac surveillance until the end of pregnancy is required. Amniocentesis is recommended.

**Postnatal management and outcome:** Surgical intervention might not be necessary at birth if there is an adequate-sized VSD and balanced blood flow to the lungs through a patent pulmonary valve. Depending on the degree of pulmonary blood flow either an aorto-pulmonary shunt (restricted flow) or pulmonary artery band (unrestrictive flow) procedure might be required during the neonatal period. This is followed by a superior caval vein to pulmonary artery shunt (Glenn) operation between 6 to 12 months of age and then finally the Fontan completion can be contemplated (total cavopulmonary shunt) from the age of three. The long-term outlook is guarded and dependent on the Fontan physiology.

### **Ebstein's anomaly**

**Definition:** Ebstein's anomaly accounts for fewer than 1% of all CHDs (2). Most cases are sporadic although there is an association with maternal lithium exposure, marijuana use and cardiac transcription factor NKX2.5, and deletions in 10p13-p14 and 1p34.3-p36.11 have also been reported (3-6). Incomplete delamination of the tricuspid valve leaflets from the right ventricle causes inferior displacement of the attachments of the septal leaflet of the tricuspid



valve relative to its annulus (Figure 4). Hence, the base of the right ventricular cavity becomes part of an enlarged right atrium leading to a much smaller contractile portion of the right ventricle confined to the apex.

**Prenatal fetures and management:** Ultrasound features are typically that the tricuspid valve orifice is displaced downwards from its usual basal position towards the cardiac apex. The tricuspid valve anterior leaflet is elongated and the septal leaflet is tethered onto the right ventricular septal wall. Tricuspid valve regurgitation and globally enlarged heart are commonly seen. Ventricular septal defect and pulmonary stenosis can be associated with Ebstein's anomaly. Non-compaction cardiomyopathy, fetal heart failure, tachycardia due to accessory pathways, severe tricuspid regurgitation, pericardial effusion and significant cardiomegaly might be observed in some cases.

Fetal management should include amniocentesis in cases exhibiting left ventricular non-compaction to exclude MYH7 mutation. A 3-4 weekly follow-up in fetal medicine would be sufficient in most cases and bi-weekly ultrasound would be necessary in severe cases.

**Postnatal management and outcome:** Long-term prognosis varies depending on the severity of tricuspid regurgitation, size of functional right ventricular cavity and the atrialised portion of the right ventricle, left ventricular and right ventricular function. Various types of tricuspid valve repair have been attempted with reasonable results. Tricuspid valve replacement may be attempted if two pump repair is feasible, or Fontan route might be undertaken in extreme cases. Long-term outlook is guarded.

### **Hypoplastic left heart syndrome (HLHS)**

**Definition:** Hypoplastic left heart syndrome encompasses an underdeveloped left atrium, diminutive and non-contractile left ventricle, critically narrowed or atretic aortic and mitral orifices, and hypoplasia of the ascending aorta (Figure 5). The left ventricle may have a bright and non-contractile appearance, described as “endocardial fibroelastosis”.

**Antenatal features and management:** In some cases, a hypoplastic left ventricle may exist with unbalanced atrioventricular septal defect in which the aortic valve may be small but patent. Severe coarctation of the aorta and physiological restriction of the foramen ovale may result in dilated right ventricle and a relatively small left ventricular cavity, which may be mistaken as hypoplastic left ventricle. If the foramen ovale becomes restrictive, fetal well-being can be threatened, therefore bi-weekly surveillance until end of pregnancy is required. Amniocentesis is recommended. Coarctation of the aorta may also co-exist. All cardiac views need to be expedited to document associated abnormalities.

**Postnatal management and outcome:** HLHS is a duct-dependent cardiac abnormality and requires prostaglandin E infusion immediately after birth to keep the baby alive. Newborn infants with this condition are very sick, and exhibit profound cyanosis and signs of congestive heart failure once the ductus arteriosus is closed and the majority will die within the first few days of life unless palliative surgery is performed. A three-stage operation with initial Norwood procedure and its modifications are the main palliative surgical interventions in the management of this severe anomaly.

### **Double inlet left ventricle (DILV)**

**Definition:** Both inlets, mitral and tricuspid valves open into a common chamber of left ventricular morphology (Figure 6). Right ventricle is hypoplastic and is located on the right or left side of the left ventricle. Other abnormalities associated with this condition include ventricular septal defect, aortic stenosis, pulmonary stenosis, and interrupted aortic arch.

**Prenatal features and management:** Fetuses are commonly asymptomatic with this anomaly. However, if there is aortic coarctation or interruption or severe pulmonary stenosis, i.e. ductus-dependent anomaly, close follow-up is necessary to ensure ductus arteriosus patency. Otherwise, usual follow up at 3-4 week intervals would suffice. Amniocentesis is recommended to exclude 22q11 chromosome microdeletion in cases with interrupted aortic

arch. Absent thymus may offer a clue in identifying cases of 22q11 microdeletion.

**Postnatal management and outcome:** Newborn babies with DILV may be breathless but are also mildly cyanosed. This condition may be duct-dependent and severity of left and right heart obstruction should be carefully assessed after birth. Surgical intervention might not be necessary at birth if there is an adequate-sized VSD, unrestrictive systemic flow, and balanced blood flow to the lungs through a patent pulmonary valve. If there is left ventricular outflow tract obstruction, further operations such as enlargement of ventricular septal defect, Damus-Kay-Stansel operation, or aortic arch repair may be required. Depending on the degree of pulmonary blood flow either an aorta-pulmonary shunt (severe pulmonary stenosis) or pulmonary artery band (unrestrictive flow) procedure might be required during the neonatal period. These are followed by a superior caval vein to pulmonary artery shunt (Glenn) operation between 6 to 12 months of age and then finally the Fontan completion can be contemplated (total cavopulmonary shunt) at the age of three. The long-term outlook is guarded.

### **Pulmonary Stenosis (PS)**

**Definition:** Pulmonary stenosis is narrowing of the pulmonary valve. PS can be mild, severe, isolated or associated with other CHDs. It can occur at subvalvar, valvar and supra-valvar levels. It is seen in approximately 7-12% of cases as an isolated abnormality or in 20-30% of patients in association with other heart defects (7-8). Neurofibromatosis, glycogen storage disease, multiple lentiginos or LEOPARD and Noonan's syndromes have increased incidence of PS (9). Supra-valvar pulmonary stenosis is most commonly associated with William's syndrome.

**Prenatal features and management:** Diagnosis of mild to moderate PS may be challenging during fetal cardiac anomaly screening unless pulmonary venous (PV) morphology is evaluated in detail from multiple planes and flow through the valve is studied with color and

pulse wave Doppler. Any turbulent flow at the PV and a peak velocity over 1 m/sec may aid diagnosing PS. Right ventricular hypertrophy, tricuspid regurgitation, and poststenotic dilation of the main pulmonary artery can be secondary diagnostic features in moderate to severe PS. In addition, retrograde flow in the ductus arteriosus can be demonstrated in severe stenosis when antegrade pulmonary blood flow is not adequate.

**Postnatal management and outcome:** PS can be treated with balloon dilatation or with surgical valvotomy in severe cases. Long-term outlook is favourable in mild or moderate cases or in patients who had good results following pulmonary valvuloplasty.

### **Pulmonary Atresia**

**Definition:** Pulmonary atresia describes a total obstruction of flow from the right ventricle to the pulmonary artery. It may coexist with or without a ventricular septal defect. Other features include varying degrees of tricuspid valve and right ventricular hypoplasia. Retrograde blood flow through the ductus can be demonstrated in pulmonary atresia with intact ventricular septum. A dilated right atrium is another finding commonly associated with this anomaly. The degree of right atrial dilatation is dependent on the amount of tricuspid regurgitation. It is imperative to identify whether the RV is tripartite and of adequate size for future biventricular repair. Tricuspid valve (TV) annulus z score of less than -3 and TV annulus to mitral valve (MV) annulus ratio of less than 0.7 is supportive of hypoplastic RV which may preclude biventricular repair. The coronary to RV sinusoids or fistulous connections may be detected in some cases with color Doppler. Colour flow through the foramen ovale should be carefully monitored for signs of developing restriction.

**Prenatal features and management:** Fetuses are commonly asymptomatic with this condition. Although rare, a restrictive foramen ovale or a restrictive ductus arteriosus may result in fetal cardiovascular compromise in some cases. Amniocentesis should be offered. Delivery should take place at a surgical center as prostin infusion will be needed at birth and a

surgical procedure or an intervention will be necessary in the first few weeks of life.

**Postnatal management and outcome:** After birth cyanosis is the main symptom and since this is a duct-dependent lesion, prostaglandin-E infusion is mandatory at birth to maintain ductal patency. Surgical correction depends on the patency and size of the tricuspid valve and the dimensions of the right ventricular cavity. Complete surgical repair of pulmonary atresia usually includes placement of a conduit between the right ventricle and pulmonary artery. If the right ventricular cavity size is diminutive then a series of palliative operations (Fontan route) will be contemplated with less favourable long-term outcomes.

### **Absent pulmonary valve syndrome (APVS)**

**Definition:** Absent pulmonary valve syndrome (APVS) is a rare anomaly characterized by the presence of a dysplastic or rudimentary pulmonary valve. It is associated in most instances with severe dilatation of the pulmonary trunk and branches due to the concurrent occurrence of valvular stenosis and severe regurgitation. Microdeletion of chromosome 22q11 is found in 21% to 38% of patients with Tetralogy of Fallot /APVS (10).

**Prenatal features and management:** Two variants of APVS have been recognized in fetal life. The most frequent one is characterized by a hypoplastic PV annulus, redundant valve like tissue at the orifice, dilated pulmonary trunk and branches, subaortic ventricular septal defect, overriding of the aorta (as in TOF) which may be associated with absence of ductal arteriosus. The rare variant is defined by the existence of an intact ventricular septum, a lesser degree dilatation of the pulmonary artery, and the presence of a patent ductus arteriosus. Significantly dilated pulmonary artery and its branches may cause obstruction to the developing tracheobronchial tree.

**Postnatal management and outcome:** The newborn may be asymptomatic or very sick depending on the degree of pulmonary flow. The outcome is adversely affected by the degree of airway hypoplasia and significant pulmonary regurgitation. Surgery is performed in early

infancy if airway obstruction is severe, otherwise it is usually contemplated when the child reaches six months of age. Current outcomes after surgical repair have been favourable once the child survives the neonatal period.

### **Tetralogy of Fallot (TOF)**

**Definition:** Tetralogy of Fallot (TOF) accounts for 5-10% of congenital cardiac defects (1) and is the most common form of cyanotic congenital heart disease (11). TOF includes four cardiac structural abnormalities: narrowing of the right ventricular outflow tract, malalignment-type VSD, overriding aorta and right ventricular hypertrophy (Figure 7). Aorta is seen straddling a large perimembranous outlet VSD. The aorta is dilated and always larger than the PA in the three-vessel and trachea views. The pulmonary valve is mostly stenosed or sometimes may be atretic. There may be multiple levels of right ventricular outflow tract obstruction.

**Prenatal features and management:** Tetralogy of Fallot might be associated with absent pulmonary valve syndrome (2.5%), atrioventricular septal defect (10%) and double outlet right ventricle (5%). The 22q11 chromosome microdeletion is not infrequently (5-10%) associated with this anomaly, however if there is absent pulmonary valve syndrome then the risk is almost 75%. In cases of atrioventricular septal defect or double outlet right ventricle the possibility of trisomy 21 should also be entertained. The four-chamber view might be completely normal but an extended apical five chamber view would help demonstrate the ventricular septal defect and the aortic override. The short-axis view is necessary to show the site of pulmonary stenosis. Fetuses are commonly asymptomatic with this condition. Management involves offering amniocentesis to exclude chromosome abnormalities such as 22q11 microdeletion and trisomy 21.

**Postnatal management and outcome:** Postnatally the most important element is the narrowing in the right ventricular outflow tract which determines the degree of cyanosis.

Some tetralogy patients may develop so called “tetralogy spells” (blue spells) where hypoxia becomes profound. Some infants may have a so called “pink Fallot” where a large ventricular septal defect dominates the clinical picture and the pulmonary stenosis is relatively mild; in such cases dyspnoea is the main symptom and the oxygen saturation is usually normal. Total surgical correction is usually performed in infancy before the child’s first birthday unless tetralogy spells develop earlier, in which case an interim aorto-pulmonary shunt procedure may be required. After total correction children lead a reasonable quality of life but 10-25% will require repeat operation such as pulmonary valve replacement by early adulthood.

### **Double outlet right ventricle (DORV)**

**Definition:** The term ‘double outlet right ventricle’ (DORV) is used if the aortic override is more than 50% or when both outflow tracts arise from the right ventricle. DORV is a conotruncal malformation representing less than 1% of all congenital heart defects (12). One complete arterial trunk and at least half of the other arterial trunk emerges from the right ventricle and there is lack of fibrous continuity between the aortic and mitral valves.

**Prenatal features and management:** The prenatal distinction of DORV from other conotruncal abnormalities such as tetralogy of Fallot may be difficult. A high incidence of aneuploidy has been reported in fetuses with DORV (13-14). Anatomy may vary greatly therefore it is important to evaluate the following parameters to provide appropriate counselling:

1. The relationship of the great arteries (normal, side-by side or transposed)
2. The position of the VSD (subaortic, subpulmonary, doubly committed or remote)
3. The presence of subpulmonary or pulmonary valvular or supra-valvar stenosis
4. The absence of mitral–aortic or mitral–pulmonary valve continuity.

**Postnatal management and outcome:** In infants with unrestrictive pulmonary blood flow and a large ventricular septal defect breathlessness, poor feeding, failure to thrive, and congestive heart failure are the main features. In some cases with severe pulmonary stenosis (as in tetralogy of Fallot or when the ventricular septal defect is in sub-pulmonary location and the aorta is situated to the right of the pulmonary artery and further away from the ventricular septum) cyanosis dominates. Postnatal management is mainly influenced by the degree of pulmonary or systemic blood flow. If pulmonary stenosis is severe then aortopulmonary shunt operation will be indicated as an interim procedure, followed by the Rastelli operation. In case of unrestricted blood flow to the lungs, pulmonary artery banding might be needed as the first intervention to prevent congestive heart failure before the final corrective surgery. If the great vessels are transposed then an arterial switch procedure combined with VSD closure would be necessary. Long term outlook would be dependent on anatomy, which may be similar to tetralogy of Fallot, transposition of the great arteries or a large VSD.

### **Transposition of the great arteries (TGA)**

**Definition:** In simple transposition of the great arteries the atriums and ventricles are arranged normally, but the aorta and the pulmonary arteries arise from the opposite ventricles, i.e. the aorta comes off the anterior right ventricle and pulmonary artery arises from the posterior left ventricle (Figure 8).

**Prenatal features and management:** The presence of other congenital anomalies such as double outlet right ventricle, single ventricle and pulmonary stenosis constitute complex transposition of the aorta which requires special management according to the dominant lesion. Normal crossing of the great arteries cannot be demonstrated. Three-vessel view fails to show normal arrangement of the vessels. The presence of other associated lesions



such as VSD, right or left outflow tract obstruction should be routinely evaluated. Special attention should be given to the atrial septum. An atrial septal excursion (ASE) ratio of less than 0.5 may be helpful in predicting postnatal restriction and thus the need for urgent balloon atrial septostomy (15). In addition, presence of ductus arteriosus restriction and its pulsatility index of less than 1.8 may give some warning of postnatal hypoxemia and development of pulmonary hypertension (15, 16).

During fetal life, this anomaly does not have any ill effect on fetal development unless restriction or premature closure of foramen ovale and/or ductus arteriosus develops.

Transposition of the great arteries is rarely associated with chromosome abnormality and amniocentesis is usually not undertaken.

**Postnatal management and outcome:** Delivery should be planned at a surgical center.

Prostaglandin E infusion at birth is required to keep the arterial duct open and the newborn baby alive. Postnatally, there must be adequate mixing either through the foramen ovale or via the arterial duct, otherwise this condition cannot be compatible with life. Balloon atrial septostomy may need to be carried out to create a reliable communication for adequate mixing at atrial level. Balloon septostomy provides interim palliation before total correction can be performed with the arterial switch operation. Surgery involves re-implantation of the pulmonary artery and aorta onto their correct ventricles in addition to relocating the coronary arteries into the neo-aortic root. Long-term outlook after surgical correction is favourable.

### **Truncus arteriosus**

**Definition:** This anomaly describes a single arterial trunk arising from both ventricles (Figure 9). A single artery then divides into pulmonary artery and aorta. A single semilunar valve is shared between these two arteries. Almost universally there is a ventricular septal defect below the truncal valve that provides mixing of venous and arterial blood. The truncal valve is either stenotic or regurgitant in 50% of cases. There may also be an interrupted aortic arch in

up to 10% of cases (15). Truncus arteriosus accounts for 1-2 % of all CHDs and is commonly associated with microdeletion of chromosome 22q11.

**Prenatal features and management:** Fetuses are commonly asymptomatic with this anomaly. The prenatal distinction of truncus arteriosus from tetralogy of Fallot and pulmonary atresia with a ventricular septal defect can be challenging. Usual follow up at 3-4 week intervals would suffice. Amniocentesis is recommended to exclude 22q11 chromosome microdeletion, which is frequently associated with this anomaly. Absent thymus may offer a clue in identifying cases of 22q11 microdeletion.

**Postnatal management and outcome:** Newborn babies with this condition are breathless and also mildly cyanosed. This condition is not duct-dependent and surgery invariably involves the use of a prosthetic conduit to connect the pulmonary arteries to the right ventricle, in addition to patch repair of the main arterial trunk and closure of the VSD. Following repair some patients may have residual truncal valve regurgitation or stenosis, or narrowing of the right ventricle to pulmonary artery conduit. Repeat surgical procedures to replace the narrow conduit are normal practice during childhood and adolescence.

### **Critical valvar aortic stenosis or atresia**

**Definition:** In this anomaly, the arterial exit from the left ventricle displays either stenosis or atresia. The left ventricle may be hypertrophied, dilated or hypoplastic. Ventricular septal defect or mitral valve abnormality might also co-exist, forming the Shone complex.

**Prenatal features and management:** Mild isolated aortic stenosis can easily be overlooked in the four-chamber view. Long-axis or five-chamber views are the most helpful planes to demonstrate aortic valve abnormalities. Other supportive diagnostic features include a poorly contracting left ventricle, aortic valve thickening/restriction, a varying degree of left ventricular hypertrophy and abnormal Doppler flow characteristics across the left ventricular outflow tract. As the aortic stenosis progresses left ventricular hypertrophy, dilatation,

hypokinesia and endocardial fibroelastosis can be observed as secondary findings. Aortic valve stenosis may be suspected if turbulent flow (with color Doppler) and an elevated velocity for the appropriate gestational age (with Pulse Wave Doppler) can be demonstrated. Mitral regurgitation can occur in fetuses with severe aortic stenosis because of increased left ventricular pressure. In aortic atresia, a retrograde flow in the aortic arch can be seen. In extreme cases severe aortic stenosis emerging early in the pregnancy may impair left ventricular development, which can lead to hypoplastic left heart syndrome. Fetal aortic valvuloplasty have been shown to prevent progression of aortic stenosis to hypoplastic left heart syndrome in selected cases. If the foramen ovale becomes restrictive, fetal well-being can be threatened so bi-weekly fetal cardiac surveillance is required until end of pregnancy. Amniocentesis is recommended to exclude, in particular, Williams and Turner syndromes.

**Postnatal management and outcome:** Following birth, right ventricular output alone is unable meet the metabolic demand of peripheral tissues. Prostaglandin infusion is mandatory in such cases in order to maintain effective circulation. Rapid intervention with balloon dilatation or surgery is required to relieve aortic obstruction. If the left ventricle is too small and unable to sustain the systemic circulation a similar complex surgical intervention as that performed for hypoplastic left heart syndrome might be necessary.

### **Coarctation of the aorta**

**Definition:** In this lesion, the descending aorta has a site of narrowing at the junction of the ductus arteriosus and the left subclavian artery (Figure 10). Although coarctation of the aorta is a congenital lesion it may also develop after birth following closure of the ductus arteriosus. Aortic coarctation accounts for 6-8 % of all congenital cardiac defects and is rather difficult to diagnose antenatally (1, 17).

**Prenatal features and management:** Up to 60% of patients with coarctation of the aorta may have an associated defect in the form of a bicuspid aortic valve, ventricular septal defect,

or mitral stenosis. The sagittal view is the best plane to document this abnormality. The three-vessel view may also offer help in showing a small aorta and a large pulmonary artery. There is frequent association of left superior vena cava to coronary sinus connection in fetuses with coarctation of the aorta. Diagnostic criteria include: (1) Visualization of a shelf at the region of the isthmus, (2) continuous, persistent forward flow in the isthmus on color Doppler, (3) aortic isthmus z score less than -2 (18), (4) isthmus to ductus arteriosus ratio of less than 0.74 in three vessels and trachea view (3VT) (19), (5) aortic valve annulus to pulmonary valve annulus and mitral valve annulus to tricuspid valve annulus measurement less than 0.6, (6) ratio of pulmonary artery to ascending aorta greater than 1.6, (7) bidirectional shunting at the foramen ovale (15), (8) distal displacement of subclavian artery from carotid artery on aortic arch sagittal view. Monthly fetal cardiac surveillance until the end of pregnancy is adequate. Amniocentesis is recommended to exclude Turner syndrome in female fetuses.

**Postnatal management and outcome:** Severe coarctation of the aorta is a duct-dependent lesion and therefore corrective surgery is necessary within the first few weeks of life. Surgery involves resection of the constricted area and end-to-end anastomosis of normal segments. Occasionally a subclavian arterial flap may be utilised to enlarge the narrow segment. In older children coarctation/recoarctation may be managed with balloon dilatation or stent implantation. Gore-Tex interposition grafts are infrequently used in children in the modern era. Long-term outlook is favourable, with only 4% requiring repeat operations and 25% exhibiting hypertension.

### **Interrupted aortic arch**

**Definition:** In this anomaly, there is complete discontinuity between the ascending and descending aortic segments. Interrupted aortic arch accounts for around 1% of congenital heart defects. The left ventricle ejects blood into the proximal segment of the aortic arch, but the distal aorta beyond the interrupted segment receives blood from the right ventricle through

the ductus arteriosus. A sagittal view is necessary to document this abnormality.

**Prenatal features and management:** Interrupted aortic arch can be classified according to the site of discontinuity as follows: Type A (distal to left subclavian), Type B (between the left common carotid and subclavian), and Type C (distal to the innominate artery). Type B is the most common interruption and commonly (40-60%) associated with 22q11 microdeletion. A VSD is almost always present and a bicuspid aortic valve is seen in 50% of infants. Left ventricular outflow tract obstruction is commonly seen owing to hypoplasia of the aortic root or posterior malalignment of the infundibular septum. Monthly fetal cardiac surveillance until the end of pregnancy is adequate. Absent thymus and 22q11 microdeletion are commonly associated with this anomaly. Amniocentesis is recommended to exclude Turner syndrome in female fetuses.

**Postnatal management and outcome:** This is a duct-dependent lesion and therefore life is incompatible without surgery. Infants with interrupted aorta exhibit signs of left ventricular failure and circulatory collapse owing to progressive tissue hypoxia. Prostin infusion is required after birth. Delivery should take place at a surgical centre. Surgery involves an end-to-end anastomosis of normal segments after resection of the ductal tissue. Rarely, subclavian arterial flap may be utilised to cover the interrupted segment. A Gore-Tex interposition graft might be required in difficult cases. Long-term outlook is favourable.

### **Anomalous pulmonary venous connection**

**Definition:** In this abnormality, some or all of the pulmonary veins fail to connect to the left atrium. Instead they may connect to the superior vena cava, right atrium, or into the liver either directly or indirectly via a common channel. An obstructed venous channel should be excluded. Total anomalous pulmonary venous connection (TAPVC) is a rare condition, accounting for 1–3% of all cardiac malformations.

**Prenatal features and management:** This abnormality is notoriously difficult to detect antenatally with no more than 12% detection rates. Presence of non-pulsatile pulmonary vein Doppler flow may alert the sonographer for this diagnosis. The findings listed below might help establish the diagnosis:

1. Small left atrium and ventricle with dilated right heart structures
2. Inability to demonstrate a direct pulmonary venous connection to the left atrium and the presence of a confluence behind the atrium
3. The presence of any additional intrahepatic vessel between the aorta and heart can be indirect signs of intracardiac TAPVD.
4. If a dilated superior vena cava is seen, a possible abnormal pulmonary venous connection to the superior vena cava should be kept in mind.
5. The dilated coronary sinus (CS) can be an indirect sign of cardiac TAPVC to the CS.
6. Dilated hepatic veins and inferior vena cava
7. Abnormal pulse wave Doppler pattern in the pulmonary veins
8. The pulmonary venous pathway can be obstructed anywhere from the individual pulmonary veins to the site of abnormal connection. Colour Doppler flow may help demonstrate the site of obstruction.

According to the drainage site, TAPVC can be classified into four types: (1) supracardiac is the most common form (40-45% of cases), (2) cardiac (26%), (3) infracardiac (24%), and (4) mixed types (5%). Fetuses with this abnormality are asymptomatic. TAPVC is rarely associated with chromosome abnormality. Usual prenatal follow up at 4-6 week intervals is required.

**Postnatal management and outcome:** Postnatally some of these patients might exhibit very little in the way of cyanosis and diagnosis can easily be overlooked. If there is pulmonary

venous obstruction, cyanosis will be accompanied by respiratory difficulties which may frequently mimic persistent pulmonary hypertension of the newborn. Surgical treatment involves re-implantation of pulmonary veins into the left atrium. Once corrected most patients remain asymptomatic with no major long-term issues. If intrapulmonary section of pulmonary veins becomes obstructed then long-term outlook may be guarded.

## **Discussion**

There are several maternal challenges (such as obesity and previous abdominal surgery), fetal challenges (such as fetal position/lie and other extracardiac anomalies) and technical challenges in the antenatal detection of congenital heart disease. Furthermore, when the screening workforce are inadequately equipped/trained and are mandated to follow sub-optimal screening protocols the diagnosis of some major cardiac anomalies might be adversely affected. Even so-called 'low-risk pregnancies' in fact harbor a larger percentage of cases with congenital heart anomalies (20, 21). In our opinion, a higher proportion of congenital heart disease cases would be detected antenatally if the ultrasonographers working in fetal medicine units were more robustly supported. Such support would include the provision of high-quality continuous learning opportunities to develop and maintain advanced ultrasound screening skills.

The four-chamber view (4CV) has been the most widely used imaging plane for fetal cardiac anomaly screening to date. Unfortunately, this view has severe diagnostic limitations: many major heart defects (including double-outlet right ventricle, tetralogy of Fallot, transposition of the great arteries, common arterial trunk, mild semilunar valve stenosis and aortic arch anomalies) might have a normal four-chamber view and so their diagnosis using this view alone would be missed. Even for the most skilled operators the detection rate of CHD using the 4CV alone would barely reach 60% according to our experience. When the

4CV and the outflow tract view (OTV) are used together the overall detection rate of CHD in antenatal life can be improved to approximately 70-90%.

Recently the three-vessel and tracheal view (3VTV) has been incorporated into some national fetal anomaly screening programmes. In our opinion 3VTV, if used concomitantly with the sagittal ductal arch and aortic arch views, is likely to significantly increase the diagnosis of great vessel abnormalities.

The prenatal detection rate of some severe CHDs (such as total anomalous pulmonary venous connection, valvar aortic and pulmonary stenosis, and coarctation of the aorta) is notoriously lower than the anticipated, varying between 8-25% (22-24). The poor detection rates of these conditions might be attributed to their relative infrequency and the normal appearance of heart chambers and great vessels at 20 weeks' gestation. Inclusion of fetal biometry (z-score assessment of cardiac structures) and both colour and pulse wave Doppler modalities into the routine 20-week anomaly screening protocols may increase the detection of such abnormalities in low risk pregnancies.

Specialist operators undertaking antenatal anomaly screening in the general pregnant population might come from diverse backgrounds. These operators might include fetal medicine specialists, obstetricians, radiologists, radiology sonographers, echocardiographers and midwife sonographers. When an operator suspects the presence of a cardiac anomaly a referral is made to a fetal cardiologist for a specialist opinion. It is not uncommon for the fetal cardiologist to perform this subsequent ultrasound examination of the fetus alone, outside of an obstetric or fetal medicine service. However, it would be preferable for fetal medicine specialists and fetal cardiologist to work together within a team to make a holistic specialist assessment of the baby with a suspected cardiac anomaly. There are many advantages of an integrated unit led by a fetal medicine specialist, or an obstetrician with an interest in fetal



medicine. First, a fetal medicine sonographer has a more focused viewpoint to investigate the fetus and mother as a whole unit. Second, as these experts are already involved in pregnancy care and anomaly screening they become more alert to other system abnormalities associated with cardiac pathologies. Third, fetal medicine sonographers have been monitored by robust clinical governance procedures and practice standards set out by professional regulatory bodies.

Ultimately, national fetal anomaly screening policies must to be supported by appropriate resources: staffing levels and procurement of the highest quality ultrasound equipment must be prioritized to achieve a robust service, whilst life-long training opportunities must be provided to sustain the skillset of the screening workforce. Most importantly, clinical governance must be an integral part of the screening service: high-quality audits and patient feedback activities must be undertaken to monitor and improve the quality of care delivery.

## **Conclusion**

The fetal echocardiogram undoubtedly provides invaluable information about the cardiovascular status of the fetus. It uniquely facilitates the diagnosis of cardiac defects that allows obstetricians, neonatologists and pediatric cardiologists to form a management plan for the remainder of the pregnancy, for delivery and for postnatal care. However, structural and functional evaluation of the fetal heart requires detailed knowledge of fetal physiology and the anatomy of CHDs, as well as expert fetal ultrasound scanning skills. The finding of a 'normal' fetal heart remains as important a challenge as the diagnosis of any cardiac anomaly. Assessment of the fetal heart in both low-risk and high-risk patients requires equivalent levels of attention, expertise and experience. Some CHDs occur in isolation whilst a substantial number are associated with multiple lesions, so fetal ultrasound examinations should

proceed with the utmost care until all segmental anatomy has been interrogated. Multiple imaging modalities such as 2D, M-mode, pulse wave and color flow Doppler might need to be incorporated within each of the recommended fetal cardiac views to ensure that all available diagnostic information is obtained.

**Contribution of Authors:** OU was commissioned to write the paper and also coordinated contribution of all authors. BKB and OU together wrote, reviewed, and edited the paper. GG, KB, GB, ML equally contributed to critical appraisal and writing of the paper.

Figures

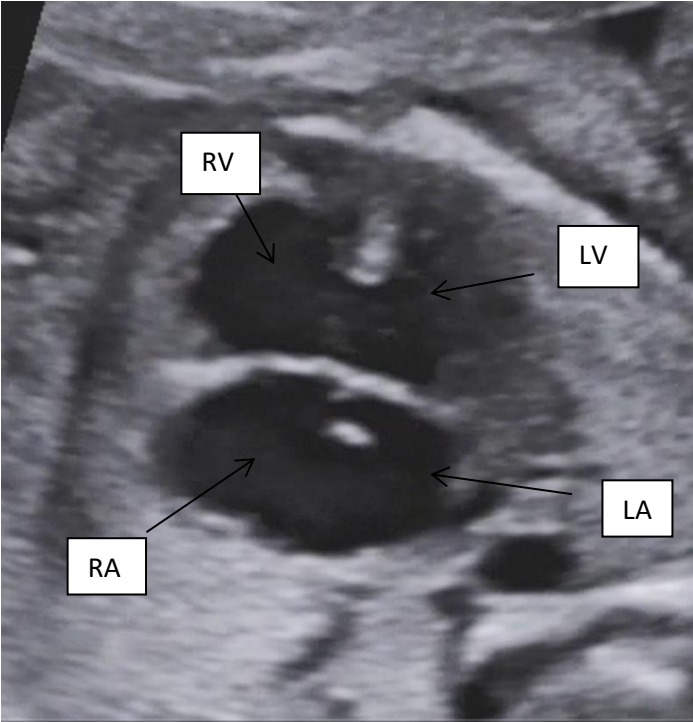


Figure 1. Atrioventricular septal defect. RV: right ventricle LV: left ventricle RA: right atrium LA: left atrium.

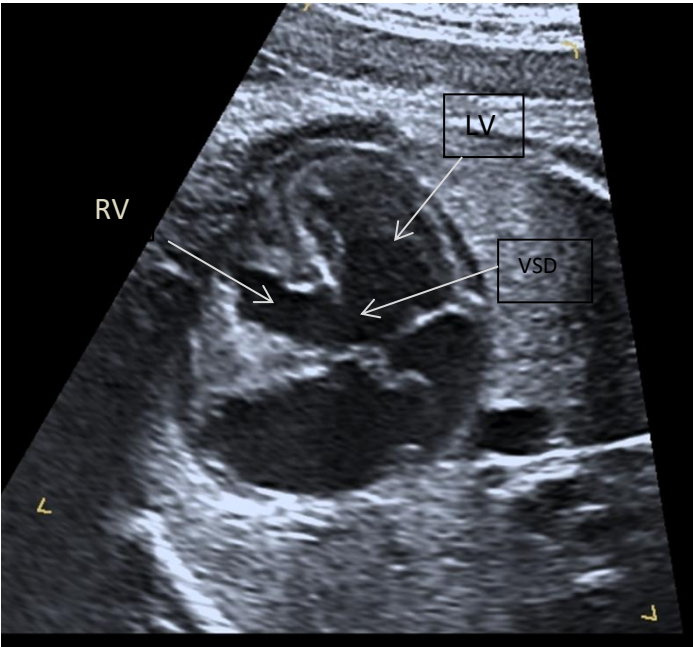


Figure 2. Ventricular septal defect. RV: right ventricle LV: left ventricle VSD: ventricular septal defect.

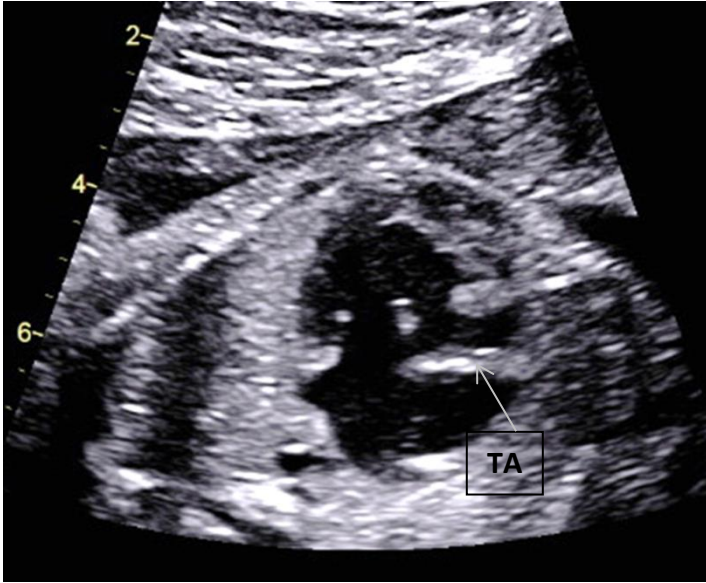


Figure 3. Tricuspid Atresia.

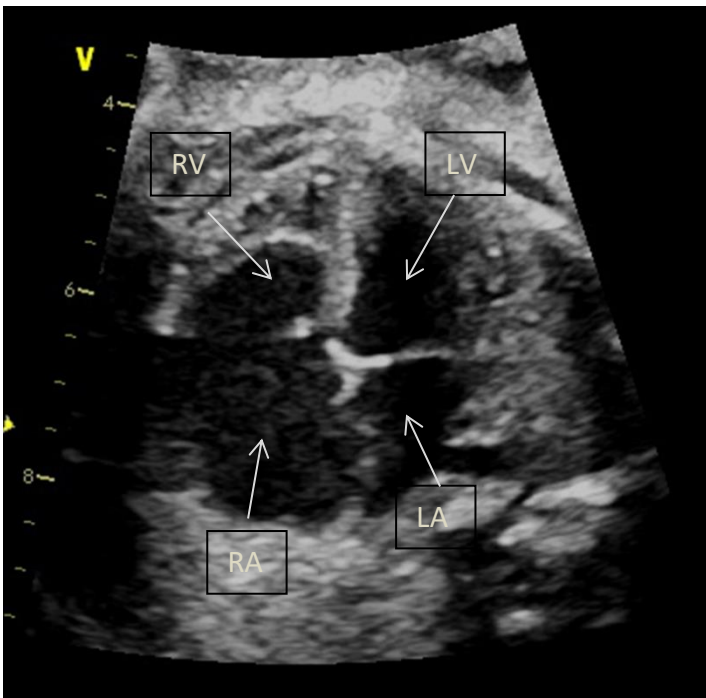


Figure 4. Ebstein's anomaly of the tricuspid valve. RV: right ventricle LV: left ventricle RA: right atrium LA: left atrium.

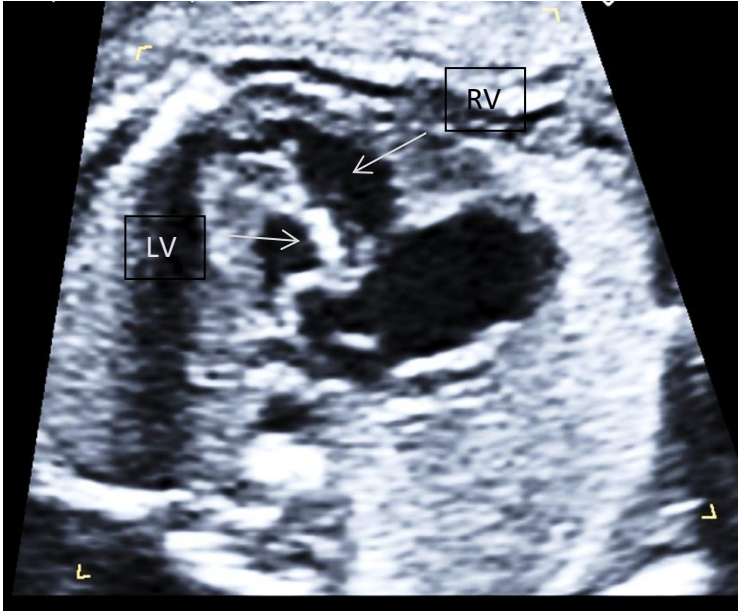


Figure 5. Hypoplastic left heart syndrome. RV: right ventricle LV: left ventricle

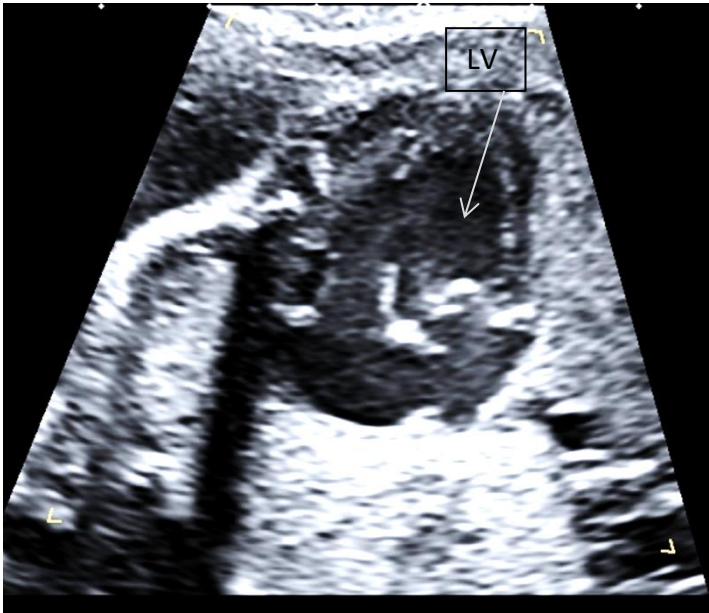


Figure 6. Double inlet left ventricle. LV: left ventricle

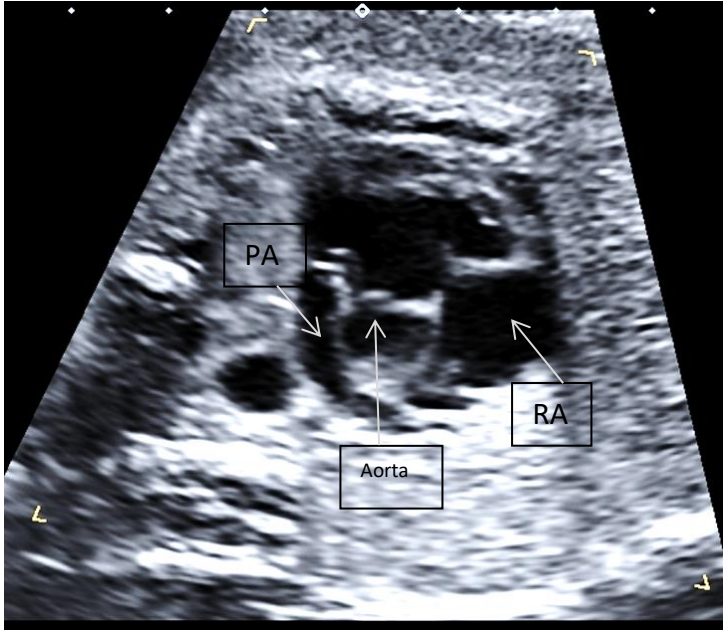


Figure 7. Tetralogy of Fallot from the parasternal short axis view. PA: Pulmonary artery. RA: right atrium.

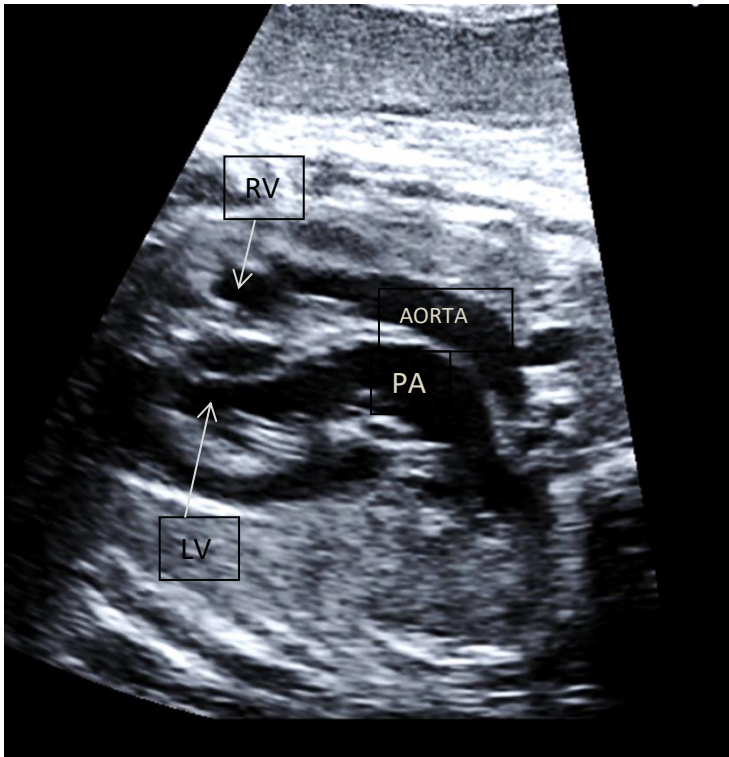


Figure 8. Transposition of the great arteries showing parallel great vessels. RV: right ventricle LV: left ventricle PA: pulmonary artery.



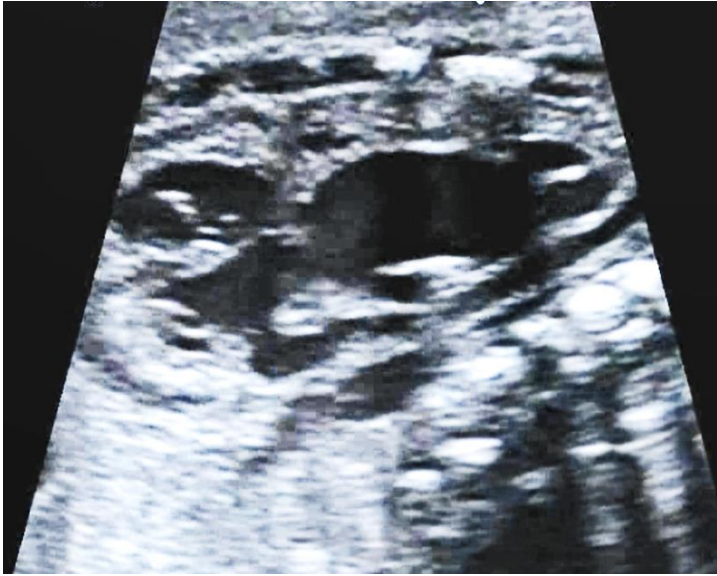

Figure 9. Truncus arteriosus showing an overriding single semilunar valve and pulmonary artery arising from its side.

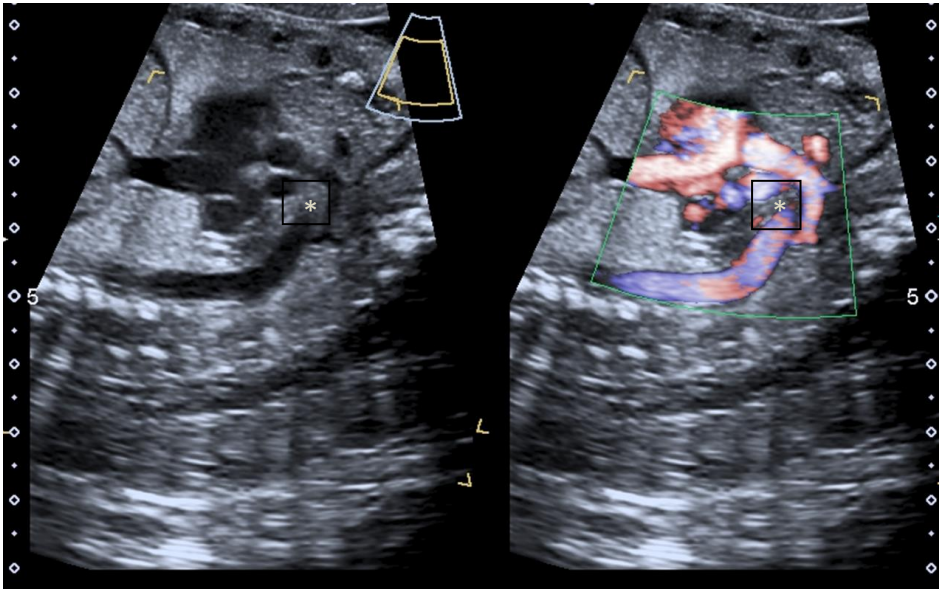


Figure 10. Coarctation of the aorta.

## Tables

**Table 1. Classification of congenital heart disease according to their best diagnostic screening plains**

### **A. Defects that can be detected from the four-chamber view**

- Atrioventricular septal defect
- Ventricular septal defects
- Mitral atresia
- Tricuspid atresia
- Ebstein's anomaly
- Hypoplastic left heart
- Double inlet left ventricle

### **B. Defects that require diagnosis using the outflow tract view**

- Pulmonary stenosis (narrowing) or atresia
- Absent pulmonary valve syndrome
- Tetralogy of Fallot
- Double outlet right ventricle
- Transposition of the great arteries
- Truncus arteriosus
- Aortic stenosis or atresia

### **C. Defects that require diagnosis using three-vessel trachea and aortic arch views**

- Coarctation of the aorta
- Interruption of the aorta
- Right or double aortic arch

### **D. Defects that require diagnosis using four-chamber, outflow tract, great veins and liver views**

- Total anomalous pulmonary venous connection
- Systemic venous connection abnormalities



**Table 2. Frequency of congenital heart diseases and their associations**

<b>Heart Defect</b>	<b>Frequency In Fetal CHD (%)</b>	<b>Incidence/1000 Live birth</b>	<b>Detection Rate (%)</b>	<b>Termination Rate (%)</b>	<b>Genetic Associations</b>
<b>Atrioventricular Septal Defect</b>	5-16	0.35	56-70	6-40	35-47%; 40% associated with Trisomy 21, 20% with Trisomy 13 and 18
<b>Ventricular Septal Defect</b>	5-16	1.1-3.57	7-50	0-5	Inlet: 37-48% Outlet: 10-40% 22q11 Muscular: 3-5%
<b>Mitral Atresia</b>	<1%	0.06-0.25	40-95	30-50	8% Trisomy 13, 18 or 11q deletion
<b>Tricuspid atresia</b>	1-3	0.03-0.5	40-80	30-59	2-9%: 8% associated with 22q11 deletion
<b>Ebstein's Anomaly</b>	0.3-0.7	0.06-0.11	59-80	6-44	0-12%, may be associated with trisomy 21
<b>Hypoplastic Left Heart Syndrome</b>	4-16	0.14-0.27	63-95	36-63	4-15% association with chromosome abnormalities, most commonly with Turner syndrome
<b>Double Inlet Left Ventricle</b>	0.07-1	0.05-0.1	30-50	51-55	Translocation (2;14), deletion (p22; q24.3)
<b>Critical pulmonary Stenosis</b>	2-6.5	0.16-0.26	31-50	13 (associated with critical PS and hypoplastic RV)	4-5%. 22q11, Noonan's, Costello, Leopard, Alagille and William's syndromes
<b>Pulmonary Atresia</b>	3-4	0.08-0.1	31-50	40 (associated with hypoplastic RV and complex CHD)	20-40% 22q11 (when associated with VSD) , aneuploidy, triploidy, trisomy
<b>Absent Pulmonary Valve Syndrome</b>	<1	0.05-0.1	30-40	30-50	75% association with 22q11 deletion
<b>Tetralogy of Fallot</b>	3-7	0.24-0.56	15-69	0-17	11-27% association with 22q11 deletion, 5q11.2 microdeletion,

					22q11.2 microduplication and trisomy 21
<b>Double Outlet Right Ventricle</b>	1-2	0.05-0.16	50-65	31-56	11-27% association with 22q11 deletion, 8p23 microdeletion and Trisomy 21
<b>Transposition of the Great Arteries</b>	2.5-5	0.24-0.4	72-85	0-14	0-3%
<b>Truncus Arteriosus</b>	1-2	0.05-0.16	18-50	20-35	4-33% association with 22q11 deletion
<b>Critical Aortic Stenosis or Atresia</b>	<1	0.04-0.5	5.3-9.2	20-35	4%
<b>Coarctation of Aorta</b>	8-9	0.03-0.18	16-42	0-4	5-19%
<b>Interrupted Aortic Arch</b>	<1	0.003	16-42	0-4	5-40% 22q11 (type-B interruption most common association)
<b>Anomalous Pulmonary Venous Connection</b>	0.6-3	0.06-0.09	0-12	0-10	0%

**Table 3. Best scanning planes and key features of congenital heart anomalies**

<b>Heart Defect</b>	<b>Scanning planes</b>	<b>Other key features</b>	<b>Outcome</b>
<b>Atrioventricular Septal Defect</b>	<b>Four chamber:</b> Primum atrial septal defect, common inlet valve, inlet VSD, loss of AV	Left/right inlet valve regurgitation 50%	<2% operative mortality

	<p>valve off-setting (atrioventricular valves at the same level), atrioventricular valve regurgitation, chamber discrepancy.</p> <p><b>Short axis:</b> Normal or atrioventricular valve regurgitation</p> <p><b>Long axis:</b> Aortic valve to apex distance longer than mitral valve to apex, great vessel orientation, atrioventricular valve regurgitation.</p> <p><b>Three vessel tracheae:</b> Normal, if no great vessel anomaly</p>	<p>With TOF 10-25%</p> <p>With isomerism 15-20%</p>	<p>95% survival at 20 years,</p> <p>25% reoperation rate for AV valve regurgitation</p>
<b>Ventricular Septal Defect</b>	<p><b>Four chamber:</b> Inlet VSD, muscular VSD, communication between the right and left ventricle</p> <p><b>Short axis:</b> inlet, and outlet VSD, communication between the right and left ventricle</p> <p><b>Long axis:</b> Outlet, and muscular VSD, communication between the right and left ventricle</p> <p><b>Three vessels and tracheae:</b> Normal</p>	<p>75% perimembranous type as in Tetralogy of Fallot and DORV</p> <p>10-15% muscular</p> <p>5% outlet: Truncus</p> <p>5-8% inlet type: AVSD</p>	<p>&lt;2% operative mortality</p> <p>Risk of complete heart block postoperatively</p> <p>Excellent long-term outlook</p>
<b>Mitral Atresia</b>	<p><b>Four chamber:</b> Atretic left inlet valve, small left ventricle, VSD or intact ventricular septum, reverse flow through foramen ovale</p> <p><b>Long axis:</b> Atretic left inlet valve, small aortic root, reverse flow through foramen ovale</p> <p><b>Short axis:</b> Normal or small aortic root</p> <p><b>Three vessel and trachea:</b> Small aortic root</p>	<p>Extracardiac abnormalities: 5%</p> <p>Associated anomalies: TGA, PS, cor-triatriatum, coarctation of the aorta</p>	<p>&gt;90% survival with arterial shunt, &gt;98% survival with Glenn operation and &gt;98% survival with Fontan operation,</p> <p>85% survival at 10 years</p>

<p><b>Tricuspid Atresia</b></p>	<p><b>Four chamber:</b> Atretic right inlet valve, small right ventricle, VSD or intact ventricular septum, exclusively right to left flow through foramen ovale</p> <p><b>Short axis:</b> Normal or small aortic root or small pulmonary artery</p> <p><b>Long axis:</b> Normal or small aortic root, small pulmonary artery, great vessel orientation normal or transposed</p> <p><b>Three vessel and trachea:</b> Normal or small aortic root or small pulmonary artery, anterior aorta if arteries transposed</p>	<p>Atretic right inlet valve</p> <p>Small right ventricle</p> <p>VSD or intact ventricular septum</p> <p>Associated cardiac anomalies: 25% TGA, 3% CCTGA</p>	<p>&gt;90% survival with arterial shunt, &gt;98% survival with Glenn operation, &gt;98% survival with Fontan operation</p> <p>85% survival at 10 years</p>
<p><b>Ebstein's Anomaly</b></p>	<p><b>Four chamber:</b> Apically displaced tricuspid valve, sail like elongated anterior leaflet, large right atrium, small right ventricle</p> <p><b>Short axis:</b> Normal or small pulmonary artery, right ventricular inflow deviated towards right ventricular outflow</p> <p><b>Long axis:</b> Normal left inlet valve, Small right ventricular cavity</p> <p><b>Three vessel and trachea:</b> Small pulmonary artery</p>	<p>Enlarged right atrium/globally enlarged heart</p> <p>Apically displaced tricuspid valve</p> <p>Small right ventricular cavity</p> <p>Severe tricuspid regurgitation</p> <p>30% VSD or pulmonary stenosis</p> <p>30-50% accessory pathways/arrhythmias</p>	<p>Intrauterine mortality up to 45-100 % in severe cases, up to 90% survival in mild cases</p>
<p><b>Hypoplastic Left Heart Syndrome</b></p>	<p><b>Four chamber:</b> Small non-contractile left ventricle, bright endocardium-endocardial fibro-elastosis, compensatory enlargement of the right ventricle, restrictive atrial septum, patency and size of left inlet valve, small left atrium</p> <p><b>Short axis:</b> Small aorta, large pulmonary artery</p> <p><b>Long axis:</b> Severely narrow or atretic left inlet valve,</p>	<p>Check foramen ovale restriction</p> <p>Check aortic arch for coarctation and</p> <p>Check endocardial fibro-elastosis</p>	<p>20% IU death, &gt;85% survival after stage 1 Norwood and &gt;98% survival after Glenn and Fontan</p> <p>50% survival in 10 years</p>

	<p>hypoplastic left ventricular outflow tract, hypoplastic/atretic aortic valve and ascending aorta</p> <p><b><u>Three vessel and trachea:</u></b> Small ascending aorta, transverse and descending aortic arches, reverse flow into the thin aorta from the ductus arteriosus</p>		<p>Isolated aortic stenosis 25-year survival &gt;60-70%</p> <p>Guarded outlook.</p>
<b>Double Inlet Left Ventricle</b>	<p><b><u>Four chamber:</u></b> Small right ventricle, small right ventricle commonly gives rise to aorta, both inlet valves open into a single ventricle of left ventricular morphology</p> <p><b><u>Long axis:</u></b> parallel great arteries</p> <p><b><u>Short axis:</u></b> Normal or small aorta, large pulmonary artery</p> <p><b><u>Three vessel and trachea:</u></b> Normal or small anterior ascending aorta</p>	<p>Mitral and tricuspid valves open into a large single left ventricle</p> <p>Right ventricle hypoplastic and left sided in 40% (less often right sided 25% and 33% common inlet)</p> <p>Right ventricle usually gives rise to aorta as an outlet chamber via a VSD (85%)</p> <p>50-85% transposed great arteries or ccTGA, normal related great arteries (15% Holmes heart)</p> <p>Pulmonary stenosis or atresia in 50%</p> <p>Interrupted aorta (6%) or coarctation (26%)</p>	<p>10 year survival &gt;70%</p>
<b>Pulmonary stenosis</b>	<p><b><u>Four chamber:</u></b> Small and thickened or enlarged right ventricle, bright restrictive atrial septum</p> <p><b><u>Long axis:</u></b> Severely narrow right outlet valve</p> <p><b><u>Short axis:</u></b> Small-narrow pulmonary artery, thickened-dysplastic or severely narrow pulmonary valve</p>	<p>VSD or intact ventricular septum</p>	<p>Balloon dilatation would suffice to relieve the obstruction; surgery is needed in rare cases.</p> <p>Outlook is excellent.</p>

	<p><b><u>Three vessel and trachea:</u></b> Small-narrow pulmonary artery, reverse flow from the ductus arteriosus into the small-narrow pulmonary artery</p>		
<b>Pulmonary Atresia</b>	<p><b><u>Four chamber:</u></b> Small-thick non-contractile right ventricle, normal sized if there is VSD, compensatory enlargement of the left ventricle, restrictive atrial septum</p> <p><b><u>Long axis:</u></b> Atretic-blocked pulmonary valve</p> <p><b><u>Short axis:</u></b> Small pulmonary artery, no forward flow into the pulmonary artery</p> <p><b><u>Three vessel and trachea:</u></b> Small-narrow pulmonary artery, reverse flow from the ductus arteriosus into the small-narrow pulmonary artery</p>	<p>VSD or intact ventricular septum</p> <p>Major aorto-pulmonary collateral circulation</p>	<p>Prostin infusion at birth.</p> <p>Arterial shunt to improve pulmonary flow as an interim operation, Rastelli procedure is to follow to connect PA to the RV.</p> <p>Pulmonary atresia –IVS survival 65% at 5 years</p> <p>Pulmonary atresia –VSD survival 70% at 10 years</p>
<b>Absent Pulmonary Valve Syndrome</b>	<p><b><u>Four chamber:</u></b> Dilated and thick right ventricle, normal sized if there is VSD</p> <p><b><u>Long axis:</u></b> Dysplastic-rudimentary and narrow pulmonary valve</p> <p><b><u>Short axis:</u></b> Very enlarged pulmonary artery and branches, restrictive forward flow into the pulmonary artery and immediate regurgitation</p> <p><b><u>Three vessel and trachea:</u></b> Large pulmonary artery, reverse flow from the ductus arteriosus into pulmonary artery or no ductus arteriosus</p>	<p>Dilated pulmonary artery and branches</p> <p>Severe pulmonary artery stenosis and regurgitation</p> <p>VSD in subaortic position with aortic override</p>	<p>Surgery is similar to tetralogy of Fallot but also require reduction of pulmonary artery size if there is any airway obstruction.</p>
<b>Tetralogy of Fallot</b>	<p><b><u>Four chamber:</u></b> Normal or mildly hypertrophied right ventricle</p> <p><b><u>Long axis:</u></b> Narrow pulmonary valve and artery</p> <p><b><u>Short axis:</u></b> Small pulmonary artery, restricted or normal</p>	<p>90% Perimembranous outlet VSD, 10% AVSD type</p> <p>Pulmonary stenosis/regurgitation</p>	<p>Aortopulmonary shunt operation is needed if hypoxic spell occurs otherwise total correction is contemplated around 6 months of age.</p>

	<p>forward flow into the pulmonary artery</p> <p><b><u>Three vessel and trachea:</u></b> Thin pulmonary artery, may be reverse flow from the ductus arteriosus into a very thin pulmonary artery</p>	<p>Aortic override &lt;50% aligned with the right ventricle</p> <p>Right aortic arch &gt;25%</p> <p>Small ductus in 70% and not visualized in 30%</p> <p>LSVC in 10%</p>	<p>Outcome is good.</p> <p>Up to 30% reoperation for PS or regurgitation</p>
<b>Double Outlet Right Ventricle</b>	<p><b><u>Four chamber:</u></b> Normal or mildly hypertrophied right ventricle</p> <p><b><u>Long axis:</u></b> Narrow or normal pulmonary valve and artery, parallel great arteries if transposed</p> <p><b><u>Short axis:</u></b> Small or large pulmonary artery, restricted or normal forward flow into the pulmonary artery</p> <p><b><u>Three vessel and trachea:</u></b> Small or normal pulmonary artery, may be reverse flow from the ductus arteriosus into a very small pulmonary artery, anterior aorta if transposition</p>	<p>Both great arteries arising from right ventricle</p> <p>VSD subaortic 47%, subpulmonary 23%</p> <p>Pulmonary stenosis</p> <p>Transposed great arteries</p>	<p>Good outlook.</p> <p>Total correction if there is tetralogy anatomy.</p> <p>In case of transposition either arterial switch operation or Rastelli procedure will be contemplated.</p>
<b>Transposition of the Great Arteries</b>	<p><b><u>Four chamber:</u></b> Normal, VSD may be seen</p> <p><b><u>Long axis:</u></b> Parallel great arteries, normal or small aorta, normal or small pulmonary artery</p> <p><b><u>Short axis:</u></b> Anterior aorta, posterior pulmonary artery</p> <p><b><u>Three vessel and trachea:</u></b> Anterior aorta or only two vessels seen</p>	<p>Failure to show crossover of great arteries</p> <p>VSD 40-45%</p> <p>Pulmonary stenosis 30-50%</p> <p>Coarctation or interruption of the aorta 5%</p> <p>The aorta arises from the right ventricle</p> <p>The pulmonary artery arises from the left ventricle</p>	<p>Outlook is excellent after arterial switch procedure.</p>

<p><b>Truncus Arteriosus</b></p>	<p><b>Four chamber:</b> VSD with hypertrophied right and left ventricles</p> <p><b>Long axis:</b> Stenosed and regurgitant truncal valve, small pulmonary artery arising from the main trunk with no additional valve</p> <p><b>Short axis:</b> Pulmonary valve not seen, large single artery gives rise to branch pulmonary arteries and ascending aorta</p> <p><b>Three vessel and trachea:</b> Only two vessels seen, flow from the single artery into a small branch pulmonary arteries</p>	<p>Single artery arises from both ventricles and overrides VSD</p> <p>Truncal valve either narrow or leaky in more than 50%</p> <p>Biventricular hypertrophy</p> <p>VSD, right aortic arch 33%, interrupted aortic arch 10-20%</p> <p>Pulmonary artery or branches arises from the main trunk</p>	<p>Guarded outlook.</p> <p>Surgery after birth involves VSD closure and pulmonary artery to RV conduit placement.</p> <p>Early preoperative death 5-10%</p> <p>90% survival at 5 years</p>
<p><b>Critical Aortic Stenosis or Atresia</b></p>	<p><b>Four chamber:</b> Dilated left ventricle</p> <p><b>Long axis:</b> Severely narrow aortic valve, small aortic root</p> <p><b>Short axis:</b> Small or normal aorta but severely restricted forward flow into the ascending aorta</p> <p><b>Three vessel and trachea:</b> Thin aorta, reverse flow from the ductus arteriosus into ascending aorta</p>	<p>Aortic valve severely narrow or atretic</p> <p>Dilated or hypertrophied left ventricle</p> <p>Severely narrow or atretic aortic valve</p> <p>Reverse flow from the aortic isthmus back into ascending aorta</p>	<p>Balloon dilatation or Norwood operation may be needed depending on the severity of aortic hypoplasia or obstruction.</p>
<p><b>Coarctation of Aorta</b></p>	<p><b>Four chamber:</b> Dilated right ventricle, VSD, parachute mitral valve, mitral stenosis</p> <p><b>Long axis:</b> small but functioning aortic valve, small aortic root, bicuspid aortic valve, aortic valve stenosis</p> <p><b>Short axis:</b> Small aortic valve, VSD, large pulmonary artery</p> <p><b>Three vessel and trachea:</b> Small ascending aorta, large pulmonary artery, hypoplastic isthmus, flow lag from the transverse arch into the descending aorta, large ductus</p>	<p>Small ascending aorta, VSD, bicuspid aortic valve</p> <p>Small aortic isthmus (coarctation)</p> <p>Large right ventricle and pulmonary artery in compared to small left ventricle</p>	<p>Excellent outlook.</p> <p>Prostin at birth, surgery involves resection of coarctation with end to end anastomosis.</p> <p>4% recurrence and reoperation risk</p> <p>25% risk of systemic hypertension</p>



<p><b>Interrupted Aortic Arch</b></p>	<p><b><u>Four chamber:</u></b> Dilated right ventricle, VSD, small mitral valve, small LV</p> <p><b><u>Long axis:</u></b> Small aortic root, small aortic valve, aortic stenosis, normal unrestricted forward flow into the ascending aorta, lack of continuity between ascending aortic arch and the descending aorta, large pulmonary artery</p> <p><b><u>Short axis:</u></b> Small aorta, large pulmonary artery, VSD</p> <p><b><u>Three vessel and trachea:</u></b> Thin aorta, loss of V shape between the pulmonary artery, ductus isthmus and and transverse arch, large ductus</p>	<p>Small ascending aorta, VSD, bicuspid aortic valve</p> <p>Discontinuity between transverse arch and descending aorta (interruption)</p> <p>Large right ventricle and pulmonary artery in comparison to small left ventricle</p>	<p>Excellent outlook.</p> <p>Surgery is similar to coarctation of the aorta.</p> <p>2% risk of pulmonary vein stenosis</p>
<p><b>Anomalous Pulmonary Venous Connection</b></p>	<p><b><u>Four chamber:</u></b> Normal or small left ventricle, small left atrium, an abnormal channel above the left atrium, large coronary sinus, large right atrium, large right ventricle</p> <p><b><u>Long axis:</u></b> Small aortic root, large pulmonary artery</p> <p><b><u>Short axis:</u></b> Small or normal aorta but normal forward flow into the ascending aorta</p> <p><b><u>Three vessel and trachea:</u></b> Small aorta, abnormal flow near transverse arch or SVC</p>	<p>Small left sided structures</p> <p>Enlarged right heart</p> <p>Increased flow from SVC, IVC</p>	<p>Excellent outlook after redirection of pulmonary veins into left atrium.</p>

## References

1. Barboza J, Dajani N, Glenn L, Angtuaco T. Prenatal Diagnosis of Congenital Cardiac Anomalies: A Practical Approach Using Two Basic Views. *RadioGraphics*. 2002;22(5):1125-1138.
2. Correa-Villaseñor A, Ferencz C, Neill C, David Wilson P, Boughman J. Ebstein's malformation of the tricuspid valve: Genetic and environmental factors. *Teratology*. 1994;50(2):137-147.
3. Benson D, Silberbach G, Kavanaugh-McHugh A, Cottrill C, Zhang Y, Riggs S et al. Mutations in the cardiac transcription factor NKX2.5 affect diverse cardiac developmental pathways. *Journal of Clinical Investigation*. 1999;104(11):1567-1573.
4. Yatsenko S, Yatsenko A, Szigeti K, Craigen W, Stankiewicz P, Cheung S et al. Interstitial deletion of 10p and atrial septal defect in DiGeorge 2 syndrome. *Clinical Genetics*. 2004;66(2):128-136.
5. Yang H, Lee CL, Young DC, Shortliffe M, Yu W, Wright JR. A rare case of interstitial del(1)(p34.3p36.11) diagnosed prenatally. *Fetal Pediatr Pathol*. 2004;23(4):251-255.
6. Cohen LS, Friedman JM, Jefferson JW, Johnson EM, Weiner ML. A reevaluation of risk of in utero exposure to lithium. *JAMA: The Journal of the American Medical Association*. 1994;271(2):146-150.

7. Campbell M. Factors In the aetiology of pulmonary stenosis. *Heart*. 1962;24(5):625-632.
8. Driscoll DJ, Michels VV, Gersony WM, Hayes CJ, Keane JF, Kidd L, et al. Occurrence risk for congenital heart defects in relatives of patients with aortic stenosis, pulmonary stenosis, or ventricular septal defect. *Circulation*. 1993;87(2 Suppl):I114-20.
9. Burch M, Sharland M, Shinebourne E, Smith G, Patton M, McKenna W. Cardiologic abnormalities in Noonan syndrome: Phenotypic diagnosis and echocardiographic assessment of 118 patients. *Journal of the American College of Cardiology*. 1993;22(4):1189-1192.
10. Glatz J, Tabbutt S, Gaynor J, Rome J, Montenegro L, Spray T et al. Hypoplastic Left Heart Syndrome With Atrial Level Restriction in the Era of Prenatal Diagnosis. *The Annals of Thoracic Surgery*. 2007;84(5):1633-1638.
11. Maeno Y, Kamenir S, Sinclair B, van der Velde M, Smallhorn J, Hornberger L. Prenatal Features of Ductus Arteriosus Constriction and Restrictive Foramen Ovale in d-Transposition of the Great Arteries. *Circulation*. 1999;99(9):1209-1214.
12. Valsangiacomo E, Hornberger L, Barrea C, Smallhorn J, Yoo S. Partial and total anomalous pulmonary venous connection in the fetus: two-dimensional and Doppler echocardiographic findings. *Ultrasound in Obstetrics and Gynecology*. 2003;22(3):257-263.
13. Calhoun Witham A. Double outlet right ventricle. *American Heart Journal*. 1957;53(6):928-939.
14. Feller Printz B, Allan L. Abnormal pulmonary venous return diagnosed prenatally by pulsed Doppler flow imaging. *Ultrasound in Obstetrics and Gynecology*. 1997;9(5):347-349.
15. Rychik J, Tian Z. *Fetal Cardiovascular Imaging: A Disease Based Approach*. 1<sup>st</sup> ed. Saunders; 2011.
16. Paladini D, Rustico M, Todros T, Palmieri S, Gaglioti P, Benettoni A et al. Conotruncal anomalies in prenatal life. *Ultrasound in Obstetrics and Gynecology*. 1996;8(4):241-246.
17. Botto L, Correa A, Erickson J. Racial and Temporal Variations in the Prevalence of Heart Defects. *PEDIATRICS*. 2001;107(3):e32-e32.

18. Pasquini L, Mellander M, Seale A, Matsui H, Roughton M, Ho S et al. Z-scores of the fetal aortic isthmus and duct: an aid to assessing arch hypoplasia. *Ultrasound in Obstetrics and Gynecology*. 2007;29(6):628-633.
19. Matsui H, Mellander M, Roughton M, Jicinska H, Gardiner H. Morphological and Physiological Predictors of Fetal Aortic Coarctation. *Circulation*. 2008;118(18):1793-1801.
20. Stümpflen I, Stümpflen A, Wimmer M, Bernaschek G. Effect of detailed fetal echocardiography as part of routine prenatal ultrasonographic screening on detection of congenital heart disease. *The Lancet*. 1996;348(9031):854-857.
21. Cooper MJ, Enderlein MA, Dyson DC, Rogé CL, Tarnoff H. Fetal Echocardiography: Retrospective Review of Clinical Experience and an Evaluation of Indications. *Obstetrics & Gynecology*. 1995;86(4):577-582.
22. Allan L, Benacerraf B, Copel JA, Carvalho JS, Chaoui R, Eik-Nes SH, et al. Isolated major congenital heart disease. *Ultrasound in Obstetrics and Gynecology*. 2001;17(5):370-379.
23. Tegnander E, Eik-Nes S. The examiner's ultrasound experience has a significant impact on the detection rate of congenital heart defects at the second-trimester fetal examination. *Ultrasound in Obstetrics and Gynecology*. 2006;28(1):8-14.
24. ter Heide H, Thomson JD, Wharton GA, Gibbs JL. Poor sensitivity of routine fetal anomaly ultrasound screening for antenatal detection of atrioventricular septal defect. *Heart*. 2004;90(8):916-7.