



Swansea University  
Prifysgol Abertawe



## Cronfa - Swansea University Open Access Repository

---

This is an author produced version of a paper published in:

*Nursing Times*

Cronfa URL for this paper:

<http://cronfa.swan.ac.uk/Record/cronfa33884>

---

### **Paper:**

Nigam, Y. & Knight, J. (2017). Diabetes management 3: the pathogenesis and management of diabetic foot ulcers.

*Nursing Times*

---

This item is brought to you by Swansea University. Any person downloading material is agreeing to abide by the terms of the repository licence. Copies of full text items may be used or reproduced in any format or medium, without prior permission for personal research or study, educational or non-commercial purposes only. The copyright for any work remains with the original author unless otherwise specified. The full-text must not be sold in any format or medium without the formal permission of the copyright holder.

Permission for multiple reproductions should be obtained from the original author.

Authors are personally responsible for adhering to copyright and publisher restrictions when uploading content to the repository.

<http://www.swansea.ac.uk/iss/researchsupport/cronfa-support/>

**In this article...**

- Causes and complications of diabetic foot ulcers
- Diabetic foot assessment, treatment and prevention
- Effective management options for diabetic foot ulcers

# Diabetes management 3: the pathogenesis and management of diabetic foot ulcers



Nursing Times  
Journal Club

## Key points

**1** Most diabetic foot ulcers (DFUs) result from either neuropathy or ischaemia – or both

**2** Infection is secondary to the development of a DFU

**3** Gangrene is a complication of DFUs and often precipitates the need to amputate

**4** Early and continuous assessment of patients with DFUs is imperative

**5** Wound debridement is important to promote the healing of DFUs

**Authors** Yamni Nigam is associate professor in biomedical science; John Knight is senior lecturer in biomedical science; both at the College of Human Health and Science, Swansea University.

**Abstract** Two frequent features of diabetes are peripheral vascular disease leading to ischaemic lower limb extremities, and sensory neuropathy, which renders the patient prone to foot injury and vulnerable to the development of diabetic foot ulcers. This final article in our three-part series on diabetes describes the clinical features of the diabetic foot and discusses the importance of early assessment and effective management.

**Citation** Nigam Y, Knight J (2017) Diabetes management 3: the pathogenesis and management of diabetic foot ulcers. *Nursing Times*; 113: 5, 51-54.

**D** iabetes is a costly disease that takes a heavy toll both on patients and families, as well as on healthcare resources. It is estimated to affect around 3.2 million people in the UK and to take up a tenth of the NHS budget (Hex et al, 2012). Disease of the foot is one of the most frequent complications of diabetes: around 15-25% of patients will, at some point, develop foot ulceration and infection. Patients with diabetes may also develop Charcot foot (Box 1).

One of the negative outcomes of diabetic foot ulcers (DFUs) is amputation – the loss of part or all of the foot, or the foot plus a portion of the lower limb (Clerici and Faglia, 2016). Among patients with DFUs, 5-24% will have an amputation (Moawad, 2016) and the number of people who require an amputation as a result of diabetes is growing worldwide.

Five-year survival rates for amputees is generally low (51%) but it is even lower for amputees with diabetes (30.9%) and, among

the latter, almost 69% die within five years of the amputation (Aulivola et al, 2004).

## Pathogenesis

The diabetic foot results from an interplay between a number of factors: vascular disease, neuropathy, trauma and infection – the two main ones being peripheral neuropathy and peripheral vascular disease (PVD).

In type 1 diabetes, neuropathy progresses more rapidly, and structural and functional changes are more severe, than in type 2 diabetes (Sima, 2008). The underlying pathophysiology is complex and takes the form of a dying back of the nerves, the distal portions of neurons being first and more severely affected (Azahry et al, 2010). Neuropathy can affect the spinal cord, although nerve degeneration begins in the periphery and sensory nerve injury generally precedes motor nerve injury.

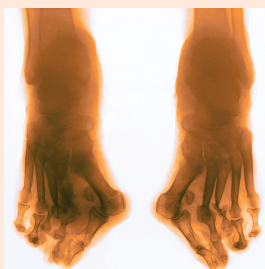Neuropathy leads to an insensitive and sometimes deformed foot, often with an irregular walking pattern. Limited joint mobility can result in abnormal,

## Box 1. Charcot foot in diabetes

Charcot foot is a non-infective, inflammatory syndrome characterised by varying degrees of bone and joint destruction, fragmentation remodelling, dislocation (commonly of the tarsometatarsal joints) and foot deformity. It has been reported in around 16% of patients with diabetes who have a history of neuropathic ulceration (Khanolkar et al, 2008). In susceptible patients with underlying neuropathy, the hallmark of Charcot foot is mid-foot collapse or 'rocker-bottom foot'.

Charcot foot is thought to occur through uncontrolled inflammation of the foot leading to osteolysis (breakdown of bone), followed by progressive fracture and dislocation (Rogers et al, 2011). The increase in blood flow means the affected foot feels warmer than the other. This may be accompanied by redness and/or swelling. Repetitive trauma to the insensitive foot propagates micro-fractures and the deformed foot becomes more prone to ulceration (Moradi et al 2014).

Charcot foot can be diagnosed early through patient history, examination and X-rays. Non-surgical treatment options include immobilisation, braces or custom shoes, and offloading pressure to help stop bone destruction (Banks, 2013).



X-ray showing Charcot foot deformity

bio-mechanical loading of the foot. Nonetheless, the patient obliviously continues walking on a desensitised foot, potentially aggravating and precipitating injuries, which may result in the development of chronic ulcers.

Dry, cracked fissures and repetitive high pressure (particularly in overweight patients with type 2 diabetes), can cause the skin of the abnormally loaded foot to thicken and calluses to form. If these are left untreated they can become thicker and break down, leading to the development of an ulcer or subcutaneous haemorrhage. If PVD is present, the result may be a painful, ischaemic foot ulcer. If neuropathy is also present, then pain perception is altered or pain is not perceived at all despite the severe peripheral ischaemia (Bit.ly/DiabetesUKNeuropathy).

### Nerve damage

Diabetic neuropathy can affect sensory, motor and autonomic functions. It creeps in slowly, usually going unnoticed by the patient (Khanolkar et al, 2008).

Sensory neuropathy renders the foot 'deaf and blind' to stimuli (Khanolkar et al, 2008), such as discomfort, temperature changes or pain. The progressive lack of these sensations allows the foot to be subjected to repetitive trauma and tissue damage.

Motor neuropathy leads to:

- Muscle atrophy;
- Foot deformity caused by an imbalance between flexor and extensor muscles;
- Altered foot biomechanics and redistribution of foot pressures, which

can eventually lead to soft tissue damage and predispose the foot to ulceration (Greenman et al, 2005).

The formation of a callus or hammer toe may lead to abnormally bony points over which diabetic foot ulcers may commonly form.

Autonomic neuropathy causes a decrease in sweat production, resulting in dry skin; this can lead to the formation of cracks and fissures that may become infected.

All of these neuropathies increase the risk of trauma caused by factors such as ill-fitting footwear, walking barefoot, injury with foreign objects or scalding (Patnaik et al, 2015).

### Peripheral vascular disease

Diabetes is associated with an increased risk of accelerated atherosclerosis (Kanter et al, 2008). As described in part 2 of this series, diabetic arteriopathy (fatty streak and plaque formation in the artery wall leading to narrowing and occlusion of the lumen) is associated with dysfunction of the endothelial lining of capillaries and of the smooth muscle cells in blood vessels. Inflammation and hypercoagulation of blood are also prominent features of the negative impact of PVD. Due to the reduced blood flow to the cells of the legs, hallmark symptoms include claudication – the pain and muscle aching that occurs in the legs when a patient walks (Knight et al, 2017).

Diabetes is most strongly associated with PVD below the knee, whereas other risk factors (such as smoking and hypertension) are associated with problems

higher up, above the knee (Chen et al, 2013). Patients with PVD also have impaired wound healing.

### Infection

Infection is not a cause but rather a consequence of DFUs: after an ulcer has developed and broken through the protective epidermis, the secondary phenomenon of infection can occur, manifesting as a red, inflamed and purulent wound. The presence of an infected ulcer has been shown to increase the risk of lower-extremity amputation by 50% compared with patients who had an ulcer that was not infected (Van Battum et al, 2011).

Most diabetic foot infections are polymicrobial but the most common pathogens are aerobic bacteria – mainly Staphylococcus species. Osteomyelitis may occur as a result of DFUs and this increases the likelihood of surgical intervention (Gemechu et al, 2013).

Gangrene often results from ischemia in combination with neuropathy, giving rise to a neuro-ischaemic foot (Boulton, 2014). Urgent assessment of the peripheral circulation is imperative and if peripheral circulation is adequate, local surgery to remove gangrenous areas can be attempted, although sometimes single toes can be left to auto-amputate (fall off by themselves). Patients with gangrene and severe distal arterial disease will require major amputations as the healing outcome from local amputations will be poor (Boulton, 2014).

***“Disease of the foot is one of the most frequent and most disastrous complications of diabetes”***

### Assessment and patient education

Diabetic foot disease is more common in males and people over 60 years of age (Rathur and Boulton, 2007). In 2005, health professionals were encouraged to examine the feet of all men aged over 60 with diabetes to determine their risk of developing foot disease (Boulton et al, 2005). Today, because early identification allows us to treat ulcers before they become severe (National Diabetes Foot Care Audit, 2016), it is recommended that all patients with diabetes are assessed holistically to identify any factors that may promote ulcer development (Wounds International, 2013).

Patients with diabetes should inspect their feet daily and should be examined by a health professional at least once every six

Table 1. Key facets of diabetic foot ulcer assessment

Assessment	Details
Examination of the ulcer	<ul style="list-style-type: none"> <li>● Size and depth of wound</li> <li>● Colour of wound</li> <li>● Wound exudate</li> </ul>
Testing for loss of sensation	<ul style="list-style-type: none"> <li>● Pinprick sensation</li> <li>● Light touch</li> <li>● Vibration</li> <li>● Pressure sensation (monofilament and tuning fork)</li> </ul>
Testing for vascular status	<ul style="list-style-type: none"> <li>● Palpate pedal pulses</li> <li>● Doppler ultrasound, ABPI (although take note that ABPI may sometimes be inaccurate for patients with diabetes)</li> <li>● Claudication</li> </ul>
Risk factors for infection	<ul style="list-style-type: none"> <li>● Probe to bone</li> <li>● Peripheral vascular disease</li> <li>● Malodour</li> <li>● Distal gangrene</li> </ul>
Structural assessment	<ul style="list-style-type: none"> <li>● High arched foot</li> <li>● Clawed toes</li> <li>● Visible muscle wasting</li> <li>● Gait changes</li> </ul>

ABPI = ankle brachial pressure index.  
Source: Adapted from Khanolkar et al (2008)

months. Table 1 summarises the key facets of DFU assessment.

The role of health professionals is also to give patients the knowledge they need to manage their condition and understand the importance of lifestyle changes (Knight et al, 2017). Patients should also be encouraged to clean and moisturise their feet daily and wear well-fitting footwear. Educating patients and families is a key part of the prevention and recognition of foot problems (Schaper et al, 2016; Bakker et al, 2012).

### Management Wound debridement

Debridement of necrotic tissue (cellular debris and cells that have died as a result of enzymatic processes) is a pre-requisite before a wound can heal. It is a key medical intervention in the management of chronic non-healing wounds (Strohal et al, 2013). In wound care for DFUs, the emphasis should be on radical and repeated debridement (Wounds International, 2013). Regular debridement removes wound debris,

non-viable tissue and infective material associated with both free-living bacteria and bacterial biofilm. There is well-documented evidence of its importance in preparing diabetic foot wounds to heal (Attinger and Wolcott, 2012).

Methods include:

- Autolytic debridement;
- Sharp debridement;
- Surgical debridement
- Hydrotherapy;
- Ultrasound and photo (light) therapy.

Biological debridement (larval therapy) is increasingly recognised as a successful way to treat diabetic, neuro-ischaemic ulcers, especially those with necrotic tissue that may be difficult to debride by other means (Boulton, 2014).

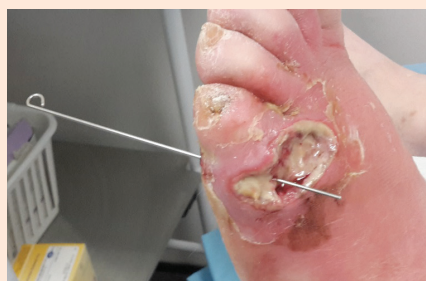### Larval therapy

Larval therapy is the application of living larvae of the greenbottle fly (*Lucilia sericata*) on the necrotic and/or infected wound bed. It has been shown to be a safe and effective method of debridement in DFUs (Gottrup and Jorgensen, 2011). A larvae dressing is left on for approximately three to four days, then reviewed and repeated if necessary. Larval therapy often produces clean, healthy granulating wounds that progress to heal very well (Fig 1).

Previously, larval therapy was considered for use only after the failure of other debridement therapies, but recently there is increased interest in its use as a first-line treatment due to the growing rate of non-healing wounds of the diabetic foot (Shi and Shofler, 2014).

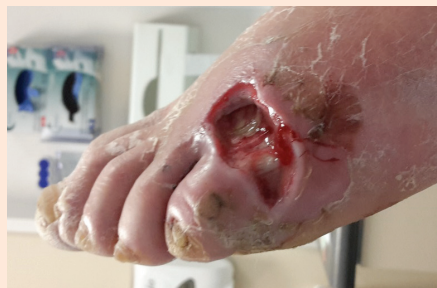There is now an abundance of scientific evidence showing exactly how larvae work

Fig 1. Diabetic foot ulcer before and after larval therapy



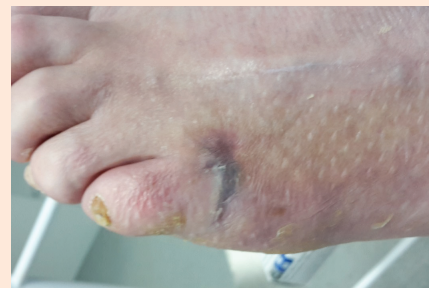1a. Foot before treatment

After initial assessment of the wound, larval therapy was discussed with the patient and it was agreed that this was the best treatment option.



1b. Foot after four days

After four days of larval therapy, the larvae were removed, revealing a fully debrided wound and an exposed tendon. Swelling and inflammation also appeared to have diminished.



1c. Foot after nine weeks

The wound progressed to healing within nine weeks of larval therapy. The patient was impressed with how rapidly the treatment had worked, and delighted that amputation could have been avoided.


Source: Images kindly supplied by Kerry Hayward-Jones, clinical specialist podiatrist, Trafford General Hospital, UK.



# Nursing Practice Review

in the wound bed, with debridement, wound disinfection and acceleration of wound healing being listed as the main larval actions (Nigam, 2016; Pritchard et al, 2016). There is also mounting clinical evidence showing that larval therapy effectively and swiftly removes devitalised tissue (Mudge et al, 2014; Waniczek et al, 2013; Zarchi and Jemec, 2012).

In their meta-analysis, Sun et al (2014) concluded that, despite some studies having methodological flaws, larval therapy significantly shortened healing time and improved healing rate of chronic ulcers. Tian et al (2013) compared larval therapy with standard care for DFUs and showed significantly better outcomes in the larval therapy group in several categories, including percentage of DFUs to achieve full healing, time to healing and amputation rate.



**5-24%** Patients with diabetic foot ulcers who will require an amputation

## Offloading

Pressure modulation, or offloading, is of great clinical importance in the management of neuropathic diabetic ulcers; recent studies have shown that proper offloading can promote DFU healing (Cavanagh and Bus, 2010).

Many offloading tools are available including crutches, wheelchairs, total cast walkers and air casts. The gold standard is considered to be the total contact casting (TCC), which has minimal padding and is carefully moulded to the shape of the foot, distributing pressures evenly over its entire surface. Using TCC has been shown to heal a higher percentage of plantar ulcers faster than standard treatments (Mueller et al, 1989). TCC use is contraindicated in patients with ischaemia due to the risk of inducing further DFUs (NICE, 2015).

## Conclusion

DFUs are one of the most serious and costly complications of diabetes. The combination of peripheral neuropathy and PVD – which so often accompany diabetes – creates an unfortunate environment for ulceration and infection of the foot, which may lead to amputation. It is vital that nurses and other health professionals know about the pathology, risk factors, assessment and treatment of the diabetic foot. Imparting good foot care education

to patients is necessary and will help achieve more acceptable and successful outcomes. **NT**

## References

**Attinger C, Wolcott R** (2012) Clinically addressing biofilm in chronic wounds. *Advances in Wound Care*; 1: 3, 127-132.

**Aulivola B et al** (2004) Major lower extremity amputation: outcome of a modern series. *Archives of Surgery*; 139: 4, 395-399.

**Azhary H et al** (2010) Peripheral neuropathy: differential diagnosis and management. *American Family Physician*; 81: 7, 887-892.

**Bakker K et al** (2012) Practical guidelines on the management and prevention of the diabetic foot 2011. *Diabetes/Metabolism Research and Reviews*; 28: Suppl 1, 225-231.

**Banks A** (2013) Can bracing have an impact for the Charcot foot? *Podiatry Today*; 26: 3.

**Boulton AJM** (2014) The diabetic foot. *Medicine*; 43: 1, 33-37.

**Boulton AJ et al** (2005) The global burden of diabetic foot disease. *Lancet*; 366: 9498, 1719-1724.

**Cavanagh PR, Bus SA** (2010) Off-loading the diabetic foot for ulcer prevention and healing. *Journal of Vascular Surgery*; 52: 3 Suppl, 37S-43S.

**Chen Q et al** (2013) Disease location is associated with survival in patients with peripheral arterial disease. *Journal of the American Heart Association*; 2: 5, e000304.

**Clerici C, Faglia E** (2016) Diabetic foot ulcers. In: Khanna AK, Tiwary SK (eds) *Ulcers of the Lower Extremity*. London: Springer India.

**Gemechu FW et al** (2013) Diabetic foot infections. *American Family Physician*; 88: 3, 177-184.


**Gotttrup F, Jørgensen B** (2011) Maggot debridement: an alternative method for debridement. *Eplasty*; 11: e33.

**Greenman RL et al** (2005). Foot small muscle atrophy is present before the detection of clinical neuropathy. *Diabetes Care*; 28: 6, 1425-1430.

**Hex N et al** (2012) Estimating the current and future costs of type 1 and type 2 diabetes in the UK, including direct health costs and indirect societal and productivity costs. *Diabetic Medicine*; 29: 7, 855-862.

**Kanter JE et al** (2008) Diabetes-accelerated atherosclerosis and inflammation. *Circulation Research*; 103: 8, e116-e117.

**Khanolkar MP et al** (2008) The diabetic foot. *QJM: Monthly Journal of the Association of Physicians*; 101: 9, 685-695.



**Nursing Times Journal Club**

To use this article for a journal club discussion with colleagues, go to [nursingtimes.net/NTJCDiabeticFoot](http://nursingtimes.net/NTJCDiabeticFoot) and download the article along with a discussion handout to give to members of your group before the meeting.

Your journal club activity counts as participatory CPD hours or can be used as the basis for reflective accounts in your revalidation activities.

For more Nursing Times Journal Club articles and tips on how to set up and run your own group, go to: [nursingtimes.net/NTJournalClub](http://nursingtimes.net/NTJournalClub)

**Knight J et al** (2017) Diabetes management 2: long-term complications due to poor control. *Nursing Times*; 113: 4, 45-48.

**Moawad M** (2016) The diabetic foot. In: David SS (ed) *Clinical Pathways in Emergency Medicine, Vol II*. London: Springer.

**Moradi M et al** (2014) Long-standing nonhealing Charcot foot ulcers that fail conservative care: is major amputation always the solution? *Wounds*; 26: 8, 239-244.

**Mudge E et al** (2014) A randomized controlled trial of larval therapy for the debridement of leg ulcers: results of a multicenter randomized, controlled, open, observer blind, parallel group study. *Wound Repair and Regeneration*; 22: 1, 43-51.

**Mueller MJ et al** (1989) Total contact casting in treatment of diabetic plantar ulcers. Controlled clinical trial. *Diabetes Care*; 12: 6, 384-388.

**NHS Digital** (2016) *National Diabetes Foot Care Audit Report 2014-2015: England and Wales*. [Bit.ly/NDFA204-15](http://bit.ly/NDFA204-15)

**National Institute for Health and Care Excellence** (2015) *Diabetic Foot Problems: Prevention and Management*. [nice.org.uk/ng19](http://nice.org.uk/ng19)

**Nigam Y** (2016) Advances in myiasis treatment. *Health Care: Current Reviews*; 4: 161.

**Patnaik PP et al** (2015) A review article on diabetic foot. *Journal of Evidence-based Medicine and Healthcare*; 2: 17, 2602-2611.

**Pritchard DI et al** (2016) TIME management by medicinal larvae. *International Wound Journal*; 13: 4, 475-484.

**Rathur HM, Boulton AJ** (2007) The diabetic foot. *Clinics in Dermatology*; 25: 1, 109-120.

**Rogers LC et al** (2011) The Charcot foot in diabetes. *Diabetes Care*; 34: 9, 2123-2129.

**Schaper NC et al** (2016) Prevention and management of foot problems in diabetes: a Summary Guidance for Daily Practice 2015, based on the IWGDF Guidance Documents. *Diabetes/Metabolism Research and Reviews*; 32: Suppl 1, 7-15.

**Shi E, Shofler D** (2014) Maggot debridement therapy: a systematic review. *British Journal of Community Nursing*; 19: Suppl Wound Care, S6-S13.

**Sima AA** (2008) The heterogeneity of diabetic neuropathy. *Frontiers in Bioscience*; 13: 4809-4816.

**Strohler R et al** (2013) The EWMA document: debridement. *Journal of Wound Care*; 22: Suppl 1, S1-S52.

**Sun X et al** (2014) A systematic review of maggot debridement therapy for chronically infected wounds and ulcers. *International Journal of Infectious Diseases*; 25: 32-37.

**Tian X et al** (2013) Maggot debridement therapy for the treatment of diabetic foot ulcers: a meta-analysis. *Journal of Wound Care*; 22: 9, 462-469.

**Van Battum P et al** (2011) Differences in minor amputation rate in diabetic foot disease throughout Europe are in part explained by differences in disease severity at presentation. *Diabetic Medicine*; 28: 2, 199-205.

**Waniczek D et al** (2013) Adjunct methods of the standard diabetic foot ulceration therapy. *Evidence-Based Complementary and Alternative Medicine*; 2013: 243568.

**Wounds International** (2013) *International Best Practice Guidelines: Wound Management in Diabetic Foot Ulcers*. [Bit.ly/WIBestPracticeDFU2013](http://bit.ly/WIBestPracticeDFU2013)

**Zarchi K, Jemec GB** (2012) The efficacy of maggot debridement therapy: a review of comparative clinical trials. *International Wound Journal*; 9: 5, 469-477.

Diabetes management series	Date
Part 1: Types, symptoms and diagnosis	April
Part 2: Long-term complications	April
Part 3: The diabetic foot	May